Chapter

# Robot-assisted Radical Cystectomy

Khurshid A. Guru,
Martin N. Jonsson,
Peter Wiklund

15

## 15.1 Introduction

In the United States, 63,000 new cases of bladder cancer will be diagnosed on a yearly basis as estimated by the American Cancer Society; of them, more than 20% will die of this disease. The incidence of bladder cancer is higher in men than in women, and it is the fourth most common cancer in men after prostate, lung, and colorectal cancer [1]. In the western world the most common etiological factors are cigarette smoking and occupational exposure to various chemicals. Treatment of bladder cancer ranges from transurethral resection of superficial bladder tumors to radical cystectomy with extensive lymph node dissection in combination with neoadjuvant chemotherapy in muscle-infiltrating cases.

Muscle-invasive urothelial urinary bladder cancer has a very high mortality rate, regardless of intensive therapeutic efforts such as radical surgery in combination with oncological treatment options. More than 50% of the patients do not survive 5 years of follow-up time, calculated on the whole bulk of muscle invasive tumors ranging from T2 to T4. In case of intraoperatively diagnosed dissemination of the cancer to regional nodes the prognosis is even worse with, 75% of the patients in this subgroup (pN1–pN2), being deceased within 3 years [2, 3].

Cystectomy performed through a laparoscopic approach was first described in 1992 [4]; however, due to relatively difficult technical problems, this treatment is still considered experimental. The introduction of robot-assisted surgery for pelvic laparoscopy, especially in performing radical prostatectomy, is starting to change the possibilities of performing complicated operations in the pelvis. Three-dimensional vision with tenfold magnification and the dexterity provided by the EndoWrist (Intuitive Surgical, Sunnyvale, Calif.; six degrees of freedom) allows the surgeon to operate the tips of the laparoscopic instruments like an open surgeon [5]. The surgeon will benefit from a faster learning curve as compared with that of conventional laparoscopy. These advantages have allowed surgeons to translate standard open surgical techniques to a minimally invasive procedure, especially its potential in operating in a narrow pelvis as well as reconstructing a urinary neobladder. The obvious next frontier in the field of pelvic oncological surgery is likely to be the utilization of the robotic assistance in cystectomy and intracorporeal creation of urinary diversion. Several series have described the possibility of laparoscopic cystectomy using conventional laparoscopy combined

with extracorporeal construction of the neobladder via a mini-laparotomy [6, 7], and multiple centers in North America and Europe have already started to use the robot for surgery in operable advanced bladder cancer [8, 9]. In contrast to laparoscopic radical prostatectomy, the numbers of such robotic series are still limited; however, various technical procedures have been described concerning both the radical cystectomy (radical cystoprostatectomy, nerve-sparing and prostate-sparing cystectomy, and anterior excentration) and the type of urinary diversion (ileal conduit, continent pouch, and neobladder). Benefits include decreased blood loss and decreased pain, which would finally translate into early recovery and quick return to normal activities especially in patients with perioperative morbidity including the obese and elderly [10]. Studies are in progress to assess benefits in decreased fluid losses, which is a direct result of operating on a closed abdominal cavity.

## 15.2 Patient Selection

Although radical cystectomy has well-recognized risks of perioperative complications and its mortality, no alternative treatment has been efficacious with minimal morbidity. In the elderly, the ability to comply with stress is reduced and there is a marked reduction in functional reserve. Patients with incidence of significant comorbid conditions should be cleared after consultation with the specialists in medicine especially for their cardiopulmonary status. In our opinion, patients who should avoid a robotic approach are patients with decreased pulmonary compliance that would not tolerate steep Trendelenburg position. Furthermore, patients with a history of previous extensive abdominal surgery may be a relative contraindication. In our experience, patients with spinal stenosis may also be at risk to develop increased neurological symptoms after long procedures in the Trendelenburg position.

## 15.3 Preoperative Preparation

After risks, benefits, and complications of all treatment options are explained, informed consent is obtained. All patients undergo a mechanical bowel preparation and are started on a clear liquid diet 24 h prior to surgery. In the preoperative area broad-spectrum intravenous antibiotics are given and a stoma site is marked. Bilateral sequential compression devices are placed. After induction of general endotracheal anesthesia, a nasogastric tube and urinary catheter are inserted. The patient is placed in lithotomy position with arms adducted and padded. The table is placed in (25–30°) Trendelenburg position. Low molecular weight heparin (4000 units) is administered preoperatively and until the patient is mobilized (14 days). Shoulder pads should be avoided due to high risk for plexus damages.

### 15.3.1 Equipment

The technique is challenging, requiring conventional laparoscopic infrastructure as well as a highly skilled assistant in conventional laparoscopy. Standard laparoscopic

surgical equipment with some extra instruments are required (Ligasure, Tyco, Norwalk, Conn.), surgical endoscopy clip applicators 5–10 mm, laparoscopy bags, and laparoscopy stapler for intestinal stapeling).

## 15.4 Port Placement

A six-port transperitoneal approach is utilized after a pneumoperitoneum is created with a Veress needle. The Veress needle is inserted at the primary supraumbilical area for the camera port. Supraumbilical position is preferred to stay proximal to the urachus. This helps in performing an easier dissection of proximal ureters and an optimal approach for an extended lymph node dissection. A pneumoperitoneum of 12 mmHg is utilized during the case, although a higher pressure of 20 mmHg is helpful in providing additional abdominal wall tension while inserting the ports. Once the peritoneal cavity is insufflated, the Veress needle is replaced with a 12 mm camera port. We prefer a 30° up lens for inserting ports as it provides clear and direct visualization of the anterior abdominal wall, although a 0° lens can also be used. The second (right) and third (left) robotic arm ports (8 mm) are placed a centimeter below the camera port, just lateral to the respective rectus muscles bilaterally and symmetrically. The fourth port (12-mm right assistance port) is placed approximately 5 cm above

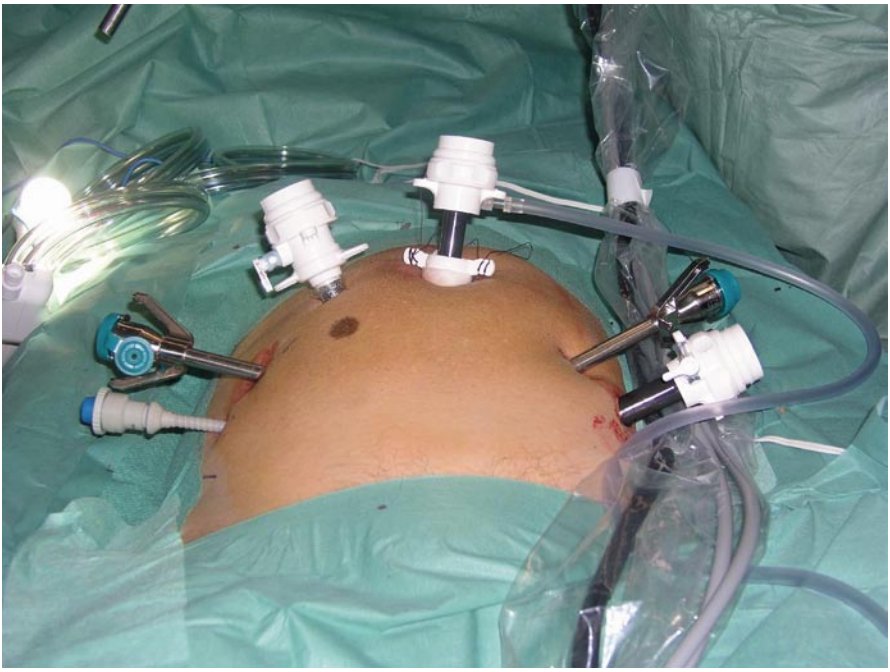

**Fig. 15.1** Final position of port placement

the right anterior superior iliac spine in the mid-axillary line. The fifth (8 mm) port is positioned approximately 5 cm above the left anterior superior iliac spine for the insertion of the fourth robotic arm instrument. It is always important to make sure the fourth arm port and the left robotic arm port are not in the same alignment to avoid clashing of the robotic arms. The sixth (5 mm) assistant port is placed midway between the right robotic arm port and the camera port approximately 2.5 cm above the camera port. After all the ports are inserted, the robot is docked and the 0° lens is used for the initial procedure. Careful inspection of the peritoneal cavity for adhesions and metastasis is performed before the start of the actual procedure. When intracorporeal construction of the urinary diversion is performed, the fourth arm port is replaced by a 12-mm port from where the laparoscopy stapler for the intestinal stapeling is inserted. Figure 15.1 shows the final position of port placement.

## 15.5 Identification and Dissection of Ureters

After evaluation of the pelvic anatomy, the ureters are dissected proximally after tracing their peristalsis across the common iliac arteries. Adequate periureteric tissue is preserved in an effort to maintain generous vascular supply. Excellent visualization with gentle handling of periureteric tissue allows for less trauma or traction, thereby decreasing the risk of ureteral strictures. After dissecting the ureters distally to the ureterovesical junction they are clipped and divided using Weck clips (Hemo-lock, Weck Pilling, N.C.). The distal margins are sent for frozen section. A stay suture may be used at the distal end of the left ureter in order to facilitate the mobilization of the left ureter under the sigmoideum.

## 15.6 Male Cystectomy

### 15.6.1 Posterior Dissection

In the male patient the dissections start by mobilization of the ureters after which the dissection starts in the plane behind the seminal vesicles. The posterior dissection starts at the level of the Douglas pouch. A 6- to 8-cm incision is made through the peritoneum and the bladder is lifted vertically by the second assistant. The ampullae and the seminal vesicles are exposed but not dissected from the bladder if a non-nerve-sparing procedure is performed. The posterior aspect of the Denonvillier's fascia is exposed and incised horizontally to expose the prerectal fat. The dissection is continued on the anterior aspect of the rectum in a fashion identical to that of a radical prostatectomy. A tunnel is created between the rectum and the prostate with the neurovascular pedicles laterally.

### 15.6.2 Lateral Dissection of the Bladder

The medial umbilical ligaments are identified close to the abdominal inguinal ring. The peritoneum is incised lateral to the ligaments and the incision is performed to the

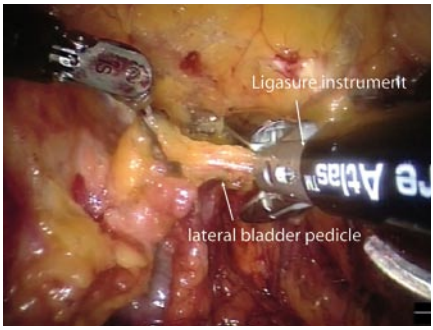


**Fig. 15.2** Dissection of the lateral bladder pedicle by the use of a 10-mm Ligasure (Tyco healthcare) instrument

medial aspect of the external iliac artery. The vas is divided to open the space medial to the external iliac vessels. At this point the umbilical ligaments and the urachus are divided at the top of the bladder. The Retzius space is opened and the bladder is dissected from the anterior abdominal wall. This is performed with a combination of sharp and blunt dissection. The dissection is carried down to the posterior aspect of the symphysis. The space between the lateral wall of the bladder and the pelvic sidewall is developed until the endopelvic fascia is reached on both sides. The superficial dorsal vein is divided on the anterior aspect of the prostate and the endopelvic fascia is opened. The lateral surface of the prostate is separated from the levator ani muscle. The prostatic apex and the dorsal vein complex is thus isolated. The second assistant may now lift the bladder at the top and the lateral pedicles can be taken down by a 5- to 10-mm Ligasure (Tyco Healthcare, Norwalk, Conn.; Fig. 15.2). The superior vesical artery is divided at its origin by means of Ligasure. The inferior vesical artery and the vesicoprostatic artery are then divided as above. The division of the pedicles is interrupted at the upper lateral aspect of the prostate to allow the preservation of the neurovascular bundles. In a non-nerve-sparing procedure the dissection is continued by means of Ligasure at this level. The neurovascular bundles on the posterolateral aspect of the prostate are easily transected in this fashion all the way down to the apex of the prostate.

### 15.6.3 Nerve-sparing Dissection

The nerve-sparing dissection is facilitated by the robotic approach due to the three-dimensional vision with tenfold magnification and the dexterity provided by the EndoWrist (Intuitive Surgical, Sunnyvale, Calif.). The nerve-sparing procedure is similar to the procedure during radical prostatectomy; however it is important not to accidentally transect the neurovascular bundles during the part of the cystectomy where the dissection is in close proximity to the neurovascular bundles. This is most important for the dissection close to the vesicles and the base of the prostate. The lateral aspect of the prostate is exposed and an incision in the lateral prostate down to the capsule along the whole lateral aspect of the prostate is performed. The rectum is then pushed downward with the suction cannula and the Denonvillier's fascia is transected close to the prostatic capsule. The vesicoprostatic pedicles are then taken down from the pros-

tate. Hemo-lock clips may be used in order to avoid cautery close to the neurovascular bundles. The risk of finding prostate cancer in these patients is not unlikely; however, the tumors are usually intraprostatic pT2 tumors and an intrafascial dissection plane may be used in order to facilitate a nerve-sparing procedure without risking positive surgical margins [11].

### 15.6.4 Apical Dissection

The vesico prostatic complex may be dissected in various ways. The use of Ligasure or the Endo-GIA with a 45-mm stapling device may be used [12]; however, we usually use a suture to secure the dorsal venous complex (2-0 Biosyn, CV25 needle). The urethra is identified and the dissection may be closer to the apical part of the prostate compared with the dissection in prostate cancer patients. A relatively long part of the urethra is dissected out before the urethra is transected. If a nerve-sparing dissection is performed, the neurovascular bundles must be protected at this level.

## 15.7 Female Cystectomy

### 15.7.1 Technique Where Four Robotic Arms Are Used

The posterior dissection of the cul de sac is performed with an inverted U incision. Vertical limbs of the incision are continued a few centimeters above the common iliac vessels bilaterally.

### 15.7.2 Control and Positioning of Uterus

Ovaries and uterus are removed depending on the tumor stage, the age of the patient, and the need for reproductive function. After dissection of the ureters is completed, the uterus is anteverted with the help of the fourth robotic arm. The infundibulopelvic suspensory ligaments along with the ovarian pedicle is identified and divided close to the uterus using either the Weck clips or the Endo-GIA with a 45-mm vascular stapler. The uterine artery pedicle can also be skeletonized and clipped or divided with the vascular stapler after it is identified and isolated. Once adequate hemostasis is achieved, the fourth robotic arm is used for retraction of the freely mobile uterus and the surrounding adnexa.

### 15.7.3 Control of Vascular Pedicle

The dissection of the bladder lateral to the umbilical ligaments is performed, which helps in isolating and defining the vascular pedicles. After transecting the round ligament, the superior vesical pedicle is clipped and divided using Weck clips. The bladder is retracted using the fourth arm with gentle traction, placing the vascular pedicle on stretch thereby separating and identifying the pedicle away form the external iliac ves-

sels while placing the vascular stapler through the right assistant port. The stapler with a vascular load is deployed, and after carefully identifying adequate distance from the external iliac vessels as well as the rectum, the stapler is fired and pedicle separated. Alternately, the anterior trunk of the internal iliac artery, which continues as the inferior vesical artery is dissected and the branches are identified and clipped using the Weck clips individually. The vascular pedicles may also be taken down using the Ligasure technique as described in the section on male cystectomy.

### 15.7.4 Vaginal Dissection

The uterus is laid on the rectosigmoid and retracted proximally with the fourth-arm assistance. The junction between the vagina and the bladder can be visually identified after filling the bladder with 100 to 150 ml of saline mixed with 5 cc of methylene blue. A sponge stick manually manipulated by the right-side assistant can help in identifying the right plane at the uterovaginal junction as well. The apex of the posterior vaginal fornix is transversely dissected at the junction of the vagina and the bladder. After passing through this layer, the sponge stick is visualized within the vaginal wall. The vaginal incision is carried anterior to either side past the urethra in a U form, ensuring that a narrow strip of anterior vaginal wall is taken en bloc with the bladder. The autonomic nerves for preservation of sexual function originate from the pelvic plexus run laterally along the vaginal wall. The excellent visualization and degree of freedom to dissect with ease helps in staying away from the perivaginal tissue within oncological norms, thereby benefiting in sexual-function preservation. If there is no history of tumor invading or approximating the uterus, hysterectomy can be performed separately. This technique is used in cases were vaginal-sparing technique is enforced to dissect the vagina carefully off the bladder. Once the bladder is removed en bloc with the anterior vaginal wall via the introitus, the uterus is lifted anteriorly and held in place with the help of the fourth robotic arm. The posterior peritoneum is incised and dissection is carried out below the vaginal fundus around the cervical insertion. The uteri with the ovaries are also removed via the vagina after placing in an endo-catch bag. In case of larger specimens, the specimen is removed via the abdominal incision after placing in the bag.

### 15.7.5 Mobilization of Bladder and Dissection of Urethra

Lateral dissection of the bladder has already been performed while isolating and dissecting the vascular pedicles. The dissection is further carried down to the perirectal space and followed along the curve of the pubic bone. The bladder is dissected off the anterior abdominal wall by incising the anterior peritoneum and transecting the medial umbilical ligaments and the urachus. The endopelvic fascia is opened.

The urethra is identified and a dorsal venous stitch or bipolar cautery is used to secure the venous complex. After identifying the external urethral meatus and the periurethral tissue with help of the proximal traction and manually manipulating the Foley catheter, dissection of the urethra is carried out intracorporeally to complete the urethrectomy, avoiding the need to undock the robot for accessing the vagina. When

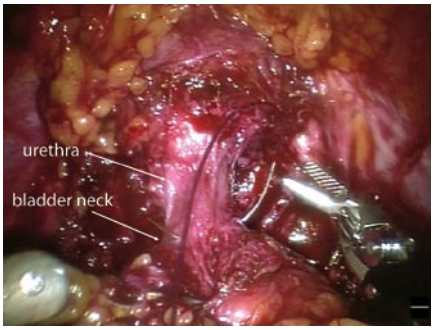


**Fig. 15.3** Dissection of the urethra and bladder neck during cystectomy in a female patient where a neobladder is scheduled to be performed. Note excellent view of the urethra and bladder neck.

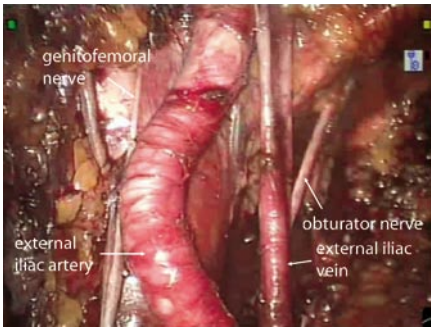


**Fig. 15.4** Dissection of pelvic lymph nodes, left side.The dissection is extended medially to the perivesical area and to the genito-femoral nerve laterally. The obturator fossa is cleared of the nodal tissue while avoiding vascular or neural injury. Excellent magnification and three-dimensional vision help in precise dissection around the vessels and nerves. The dissection is facilitated by the use of 30° down lens.

the urinary diversion is a neobladder the urethra is transected just below (5 mm) the bladder neck to ensure a functional urethal closure mechanism (Fig 15.3). The vagina may be opened between the cervical insertion and the urethra in order to retrieve the specimen through the opening in the anterior vaginal wall.

### 15.7.6 Reconstruction of the Vaginal Wall

The edges of the vaginal wall are closed using the "clam-shell technique" with a running interlocking suture [13]. We do not perform the traditional side-to-side closure of the posterior vaginal wall, as it may produce a narrow dysfunctional tubular vagina.

## 15.8 Pelvic Lymph Node Dissection

The pneumoperitoneum is decreased to evaluate for adequate hemostasis prior to proceeding to a formal lymph node dissection. The lymph node dissection is performed after the bladder specimen is placed in an endo-bag and pushed away from the pelvis or retracted through the vaginal wall incision. This approach allows clear visualization of the anatomy and easy access in performing a proper lymphadenectomy. Some centers advocate performing a lymph node dissection before the cystectomy, as the

vascular pedicle is clearly isolated after a meticulous pelvic lymph node dissection. We perform the lymph node dissection after the cystectomy as it provides wide space for us to work in a narrow pelvic cavity and the identity of the vascular pedicle is easier with the phenomenal 3D vision provided with robotic assistance. Lymph node dissection is typically started distally from the nodes of cloquet and the circumflex iliac vessels. Close attention is paid to the location of the collapsed external iliac vein to avoid injury. Adequate hemostasis is obtained by using bipolar current to cauterize small vessels and lymphatic channels draining the packet.

Dissection is carried medially by identifying the obturator nerves and vessels. The dissection is extended medially to the perivesical area and to the genitofemoral nerve laterally. The obturator fossa is cleared of the nodal tissue while avoiding vascular or neural injury (Fig. 15.4). The paravesical lymph nodes are removed en bloc with the cystectomy specimen. Excellent magnification and three-dimensional vision help in

**Table 15.1** Instruments used for each surgical step during female cystectomy

| Surgical step | Endoscope | Right robotic instrument | Left robotic instrument | Comments |
|---|---|---|---|---|
| Placement of ports and lysis of adhesions | 30° angled up | Scissors | Bipolar forceps | – |
| Dissection of ureters | 0° | Scissors | Bipolar forceps | Clips placed across distal ureteo-vesical junction; frozen section performed |
| Positioning of uterus | 0° | Monopolar scissors | Bipolar forceps | Fourth robotic arm anteverts uterus, clips placed across ovarian pedicle and uterine artery |
| Dissection of uterine support | 0° | Monopolar scissors | Bipolar forceps | Fourth robotic arm retracts the adnexa |
| Control of bladder vascular pedicle | 0° | Monopolar scissors | Bipolar forceps | Clips or vascular stapler placed across the vesical pedicles |
| Vaginal dissection | 0° or 30° angled down | Scissors | Bipolar forceps | Sponge stick in vagina |
| Mobilization of anterior aspect of bladder | 30° angled up | Monopolar scissors | Bipolar forceps | 0-Vicryl CT1 around dorsal vein complex |
| Dissection of anterior urethra including the meatus | 0° | Monopolar scissors | Bipolar forceps | – |
| Reconstruction of vaginal wall | 0° | Needle driver | Needle driver | Clam-shell closure; 2-0 Vicryl CT2 |
| Pelvic lymph node dissection | 0° or 30° angled down | Scissors | Bipolar forceps | – |

precise dissection around the vessels and nerve with ease. The dissection is facilitated by the use of 30° down lens.

Dissection is carried along the proximal portion of the common iliac artery (Fig 15.5). The common iliac artery is mobilized medially to retrieve all nodal tissue encountered. Attention needs to be paid to the amount of traction used by the robotic instruments (Table 15.1), as injuries in the area of bifurcation, especially to the internal iliac vein, can be difficult to repair. The dissection may be carried all the way up to the aortic bifurcation, removing the presacral lymphatic tissue. This will allow a lymph node dissection which is similar to the dissection in open surgery. The dissection is facilitated by placing the robotic ports a few centimeters higher up on the abdomen.

## 15.9 Robot-assisted Urinary Diversion

### 15.9.1 Robot-assisted Ileal Conduit Intracorporeal Technique

Twenty centimeters of ileum is isolated 15 cm from the ileocecal junction. The intestine may be isolated using laparoscopic Endo-GIA with a 60-mm intestinal stapler. The continuity of the small bowel is restored by using Endo-GIA with a 60-mm intestinal stapler, positioning the distal end proximal end of the ileum side to side with the antimesentery part facing each other (Fig. 15.6). The distal ends may then be closed by an additional staple row as in open surgery. Stay sutures may be used to attach the intestines before stapling them together. The left ureter is brought over to the right side under the sigmoideum. The ureteric entero-anastomosis is performed using 4-0 Biosyn with a modified Wallace technique (Fig 15.7). The ureteric stents are then introduced through the ileal segment. After the ureteric entero-anastomosis is performed, the distal end of the ileal conduit is pulled through the abdominal wall and sutured to the skin.

### 15.9.2 Robot-assisted Orthotopic Neobladder, Intracorporeal Technique

We create the orthotopic neobladder by using a 50-cm segment of ileum. The ileal segment is isolated and detubularized leaving a 10-cm intact proximal isoperistaltic Studer afferent limb. The continuity of the ileum is restored as described above. After detubilarization, we continue by performing the anastomosis between the urethra and the intestinal segment. This is important for two reasons: firstly, the anastomosis may be performed without tension; and secondly, the neobladder will be positioned in the small pelvis during the procedure and thus it will be relatively easy to perform the suturing necessary in the creation of the neobladder. The anastomosis is localized 10 cm from the distal end of the detubularized ileum. We use the Van Velthoven technique with a two times 18 cm 4-0 Biosyn suture allowing for 10–12 stitches (Fig. 15.8) [14]. After the anastomosis is finished, the posterior part of the Studer reservoir is sutured together using 3-0 Biosyn. In our first reservoirs we used an Endo-GIA 60-mm intestinal stapler to create the reservoir; however, this created some problems, such as tension in the urethra anastomosis, due to low compliance in the reservoir, and metallic clips may

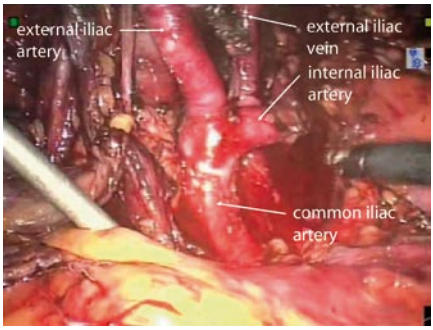


**Fig. 15.5** Dissection of pelvic lymph nodes, left side. Dissection is carried along the proximal portion of the common iliac artery. The common iliac artery is mobilized medially to retrieve all nodal tissue encountered. Attention needs to be paid to the amount of traction used by the robotic instruments, as injuries in the area of bifurcation, especially to the internal iliac vein, can be difficult to repair. The dissection may be carried all the way up to the aortic bifurcation, removing the presacral lymphatic tissue. This will allow a lymph node dissection which is similar to the dissection in open surgery.

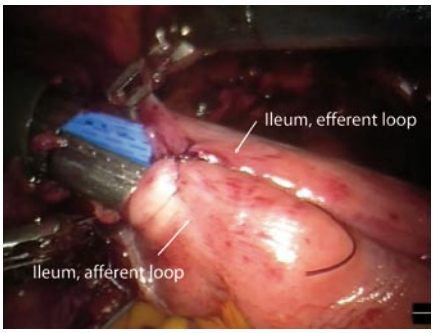


**Fig. 15.6** The continuity of the small bowel is restored by using Endo-GIA with a 60-mm intestinal stapler, positioning the distal end and proximal end of the ileum side by side with the antimesentery part facing each other. The distal ends may then be closed by an additional staple row as in open surgery. Stay sutures are used to attach the intestines before stapling them together.

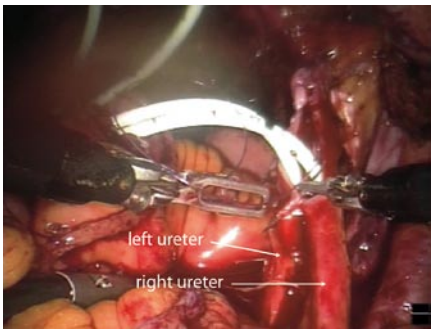


**Fig. 15.7** The ureteric entero-anastomosis is performed using 4-0 Biosyn with a modified Wallace technique. The ureteric stents are then introduced through the ileal segment and in to the left and right ureters, respectively. After this the ureteric entero-anastomosis is performed using 4-0 Biosyn.

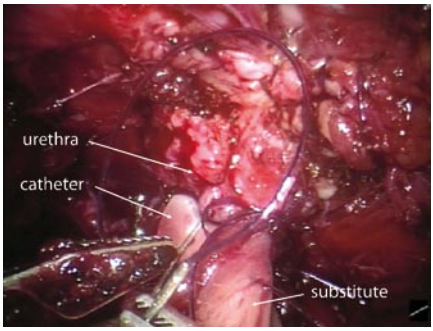


**Fig. 15.8** The anastomosis between the urethra and the intestinal segment is performed before the neobladder is created. This is important for two reasons: firstly, the anastomosis may be performed without tension; and secondly the neobladder will be positioned in the small pelvis during the procedure and thus it will be relatively easy to perform the suturing necessary in the creation of the neobladder. The anastomosis is localized 10 cm from the distal end of the detubularized ileum. We use the van Velthoven technique with a two times 18-cm 4-0 Biosyn (Tyco, Norwalk, Conn.) suture allowing for 10–12 stitches.

also cause stone formation in the reservoir. After the posterior part is sutured, we continue by suturing half of the anterior part of the reservoir. At this point the anastomosis between the ureters and the afferent limb is performed using the Wallace technique as described above. The remaining part of the reservoir is then sutured.

## 15.10 Discussion

There are several studies which have shown that laparoscopic cystectomy may be superior to open surgery in several aspects [15, 16]. Potential advantages to perform the operation laparoscopically are smaller incisions, decreased pain, shorter recovery time, decreased blood loss and fluid imbalance, and decreased hospital stay. At present, robot-assisted cystectomy has limitations such as longer operating time, more difficult lymph node dissection, and higher cost for the procedure. Increased costs in robotic surgery has been suggested to be a major disadvantage compared with open and conventional laparoscopic surgery; however, it is notoriously complicated to calculate health care costs. The cost of the robot as well as the service fee and robotic instruments increases the expense. In contrast, shorter hospital stay, faster recuperation, and decreased bleeding will decrease costs compared with open surgery. Patients are also likely to go back to work quicker after minimally invasive approach; thus, the real costs are difficult to asses and further studies are needed to address the cost issue in minimally invasive cystectomy.

One of the main questions when performing a urinary diversion after a robot-assisted cystectomy is whether to create the urinary diversion intra- or extracorporeally? When the extracorporeal technique is used, a small incision is created allowing for specimen retrieval, restoration of the continuity of the small bowel, construction of the neobladder, and the anastomosis between the ureters and the neobladder. The reservoir is then inserted in to the abdomen and the urethra anastomosis can then be performed by laparoscopy with or without robot assistance. In contrast, in the intracorporeal technique the restoration of the small bowel continuity and the construction of the neobladder is performed without incision of the abdominal wall. In the female, the specimen may be taken out through an incision in the vaginal wall and in the male the specimen is extracted through a small incision at the end of the procedure. It is unclear if the intracorporeal technique has any advantages over extracorporeal technique. It has been argued that intracorporeal approach should only be used if specimen retrieval can be performed without an additional incision [7]. It is unclear if a totally intracorporeal technique is better for the patients. It is clearly less traumatic for the patient, but it also more technically demanding for the surgeon. The robot will make an intracorporeal technique more feasible, but nevertheless it is still a challenging surgical procedure. Performing an extensive lymph node dissection is also more complicated with the laparoscopic approach regardless of whether conventional laparoscopy or robot-assisted technique is used.

There has been a tremendous increase in the number of robot-assisted prostatectomies in the United States during the past years. During 2007 more than 50% of the operations for prostate cancer are predicted to be robot assisted; thus, the number of surgeons that are skilled users of the robot will increase over time. This will possibly also lead to an increase in the number of surgeons who may perform advanced laparo-

scopic surgery in the pelvis. Accordingly, robot-assisted cystectomy may increase due to less limitation in the number of robotic surgeons.

The advantages of robotic surgery is similar to conventional laparoscopic surgery, i.e., decreased pain, decreased hospital stay, shorter recovery time, smaller incisions. These differences are easily noted by the patients and will lead to increased demand for robot-assisted treatment. In other areas of minimally invasive surgery patient-driven demand has been a major driving force and it is possible that this will be the case also in bladder cancer surgery in the future.

The next generation of robots will probably be less expensive than current systems. New instruments that will simplify as well as allow more exact dissection will be developed. Furthermore, the possibility to combine radiology and other imaging techniques with live on-line vision systems is also likely to be developed in the near future. This is likely to increase the user friendliness of future surgical robot systems.

Finally, the long-term oncological results will define the final position of robot-assisted cystectomy in the armamentarium against bladder cancer. To date, only limited data on the oncological outcome in minimally invasive cystectomy series have been presented. The only 5-year data available suggest comparable oncological outcome for laparoscopic and open surgery [17]; however, further series with longer follow-up is needed to assess the long-term results after robot-assisted cystectomy.

## References


1. Jemal A, Siegel R, Ward E, Murray T, Xu J, Smigal C, Thun MJ (2006) Cancer statistics. CA Cancer J Clin 56:106–130
2. Advanced Bladder Cancer Meta-analysis Collaboration (2003) Neoadjuvant chemotherapy in invasive bladder cancer: a systematic review and meta-analysis. Lancet 36:1927–1934
3. Larsson P, Wijkström H, Thorstenson A, Adolfsson J, Norming U, Wiklund P, Onelöv E, Steineck G (2003) A population-based study of 538 patients with newly detected urinary bladder neoplasms followed during 5 years. Scand J Urol Nephrol 37:195–201
4. Parra RO, Andrus CH, Jones JP, Boullier JA (1992) Laparoscopic cystectomy: initial report on a new treatment for the retained bladder. J Urol 148:1140–1144
5. Wiklund NP (2004) Technology insight: surgical robots – expensive toys or the future of urologic surgery? Nat Clin Pract Urol 1:97–102
6. Moinzadeh A, Gill IS, Desai M, Finelli A, Falcone T, Kaouk J (2005) Laparoscopic radical cystectomy in the female. J Urol 173:1912–1917
7. van Velthoven RF, Rassweiler J (2005) de la Rosette JMCH, Gill IS (eds) Laparoscopic urologic surgery in malignancies. Springer, Berlin Heidelberg New York, pp 97–113
8. Guru KA, Kim HL, Piacente PM, Mohler JL (2007) Robot-assisted radical cystectomy and pelvic lymph node dissection: initial experience at Roswell Park Cancer Institute. Urology 69:469–474
9. Menon M, Hemal AK, Tewari A, Shrivastava A, Shoma AM, El-Tabey NA, Shaaban A, Abol-Enein H, Ghoneim MA (2003) Nerve-sparing robot-assisted radical cystoprostatectomy and urinary diversion. BJU Int 92:232–236
10. Savage SJ (2004) Radical cystectomy: the minimally invasive approach. Urol Oncol 2:262–263
11. Curto F, Benijts J, Pansadoro A, Barmoshe S, Hoepffner JL, Mugnier C, Piechaud T, Gaston R (2006) Nerve sparing laparoscopic radical prostatectomy: our technique. Eur Urol 49:44–52

12. Ahlering TE, Eichel L, Edwards RA, Lee DI, Skarecky DW (2004) Robotic radical prostatectomy: a technique to reduce pT2 positive margins. Urology 64:1224–1228
13. Jhaveri FM, Whitesides EW, Sackett CK et al. (1998) Preservation of sexual function in women after anterior exentration for bladder cancer. Br J Urol 81:312–331
14. van Velthoven RF, Ahlering TE, Peltier A, Skarecky DW, Clayman RV (2003) Technique for laparoscopic running urethrovesical anastomosis: the single knot method. Urology 61:699–702
15. Paz A, Cytron s:, Stepnov E, Shumalinski D (2003) A prospective study between laparoscopic and open radical cystectomy. J Endourol 17:A80
16. Matin SG, Gill IS (2002) Laparoscopic radical cystectomy with urinary diversion: completely intracorporeal technique. J Endourol 1:335–341
17. Haber GP, Gill IS (2007) Laparoscopic radical cystectomy for cancer: oncological outcomes at up to 5 years. BJU Int 10:137–142