TTE Basics

Anesthesia Residency
POCUS Curriculum

Transthoracic Echocardiography

- A “point of care” ultrasound (POCUS) exam can be performed at the patient’s bedside and can be used in acute clinical situations to aid in making a diagnosis or providing a qualitative assessment of a patient.

- Advantages
  - Fast and immediate results
  - Non-invasive exam
  - Dynamic assessments
  - Serial monitoring
- Disadvantages
  - Highly user-dependent
  - Does not provide quantitative analysis

TTE in the unstable patient

- Identification of:
  - Hypovolemia (evaluation of volume status)
  - Cardiac tamponade
  - Left ventricular or right ventricular failure
  - Severe valvulopathies

Equipment

- Ultrasound machine
- TTE transducer
  - phased-array probe
- Gel

TTE Basic Exam

- 3 main windows

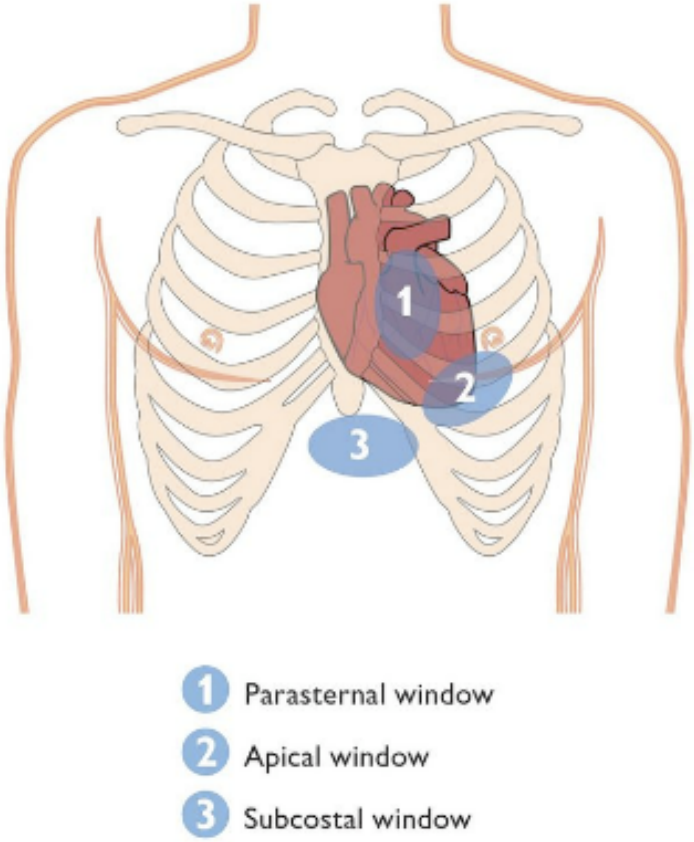

Images courtesy of: Introduction to Transthoracic Echocardiography. Philips Tutorial.

Parasternal Long Axis View

- Place transducer at the left sternal border, in the left 3rd-4th intercostal space
- Orient transducer with the probe indicator directed towards the right shoulder
- Optimal depth:
  - To view the cardiac chambers and valves: 12-16cm
  - To assess for pericardial or pleural effusions: 20-24cm

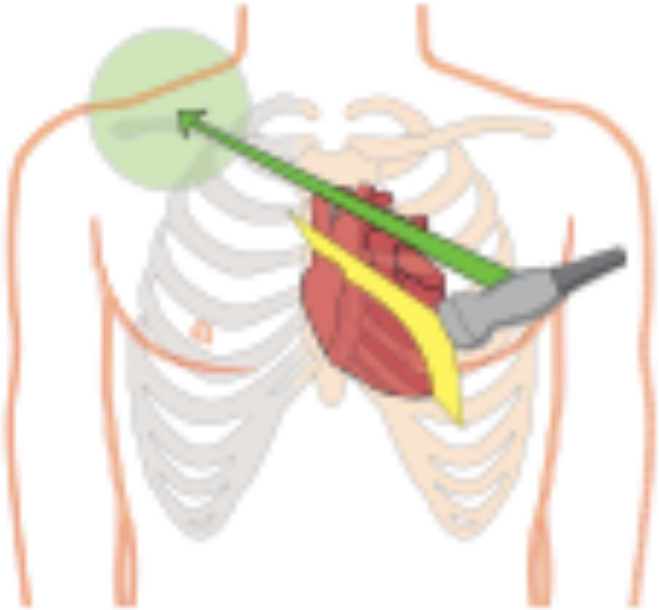

Parasternal Long Axis View

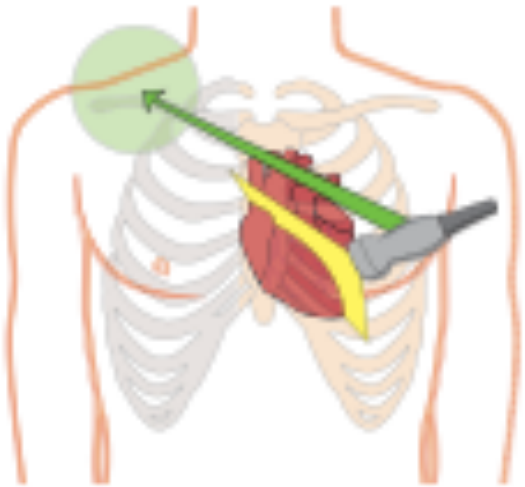

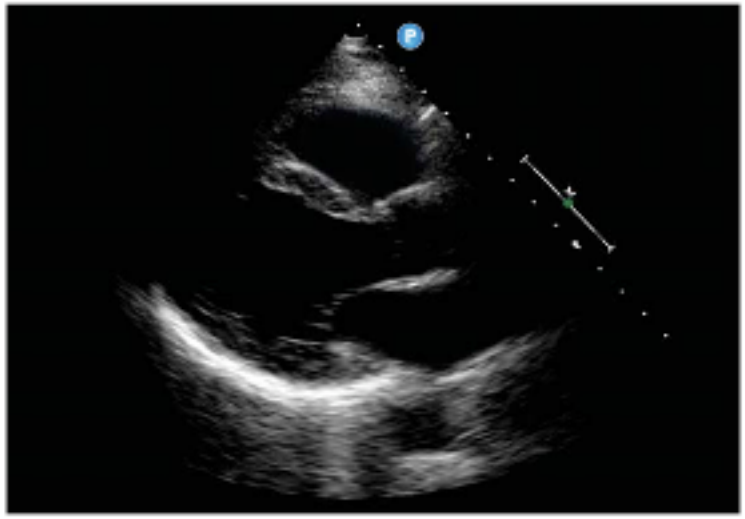

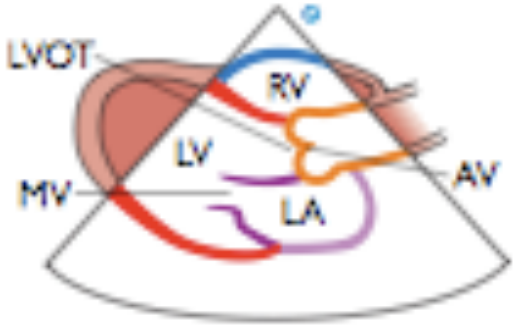

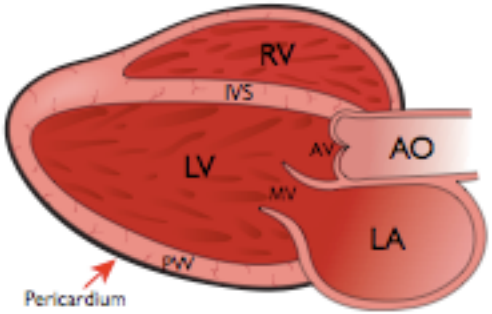

Parasternal Long Axis View

- Assessment of :
  - LV size and function
  - RV size and function
  - Interventricular Septum
  - Ascending Aorta
  - Aortic valve
  - Mitral valve
  - Pericardium (& presence of effusions)

Parasternal Short-Axis View

- From the parasternal long-axis view, rotate transducer 90° clockwise
- Indicator now points towards the left shoulder
- Tilting the transducer allows for assessment of the heart at three locations:
  - Aortic Valve
  - Mitral Valve
  - LV (@Mid-papillary level)
- Optimal depth: 12-16cm

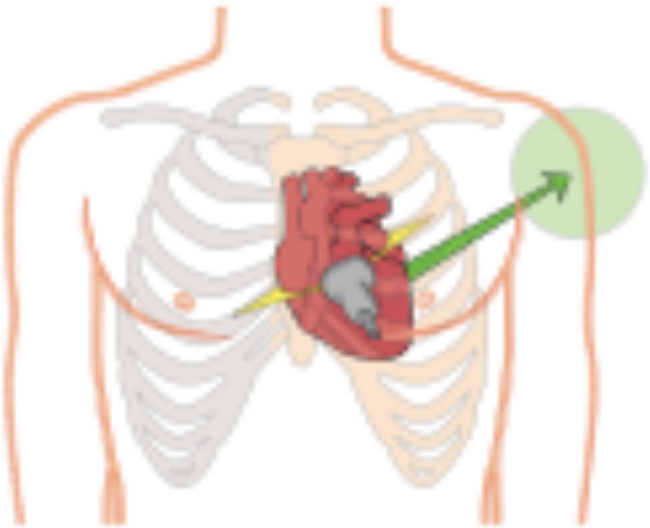

Parasternal Short-Axis View

- Three views from parasternal window are obtained by tilting the transducer from the right shoulder/head towards the feet:
  - 1) Aortic valve
  - 2) Mitral valve
  - 3) Mid-papillary


RVOT
Tricuspid valve
RA
Pulmonic valve
LA
Aortic valve

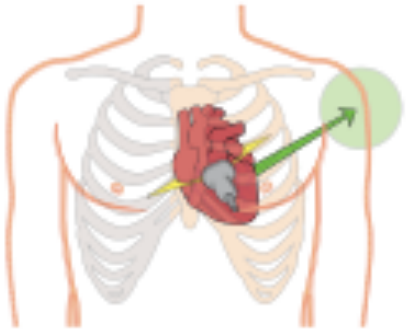

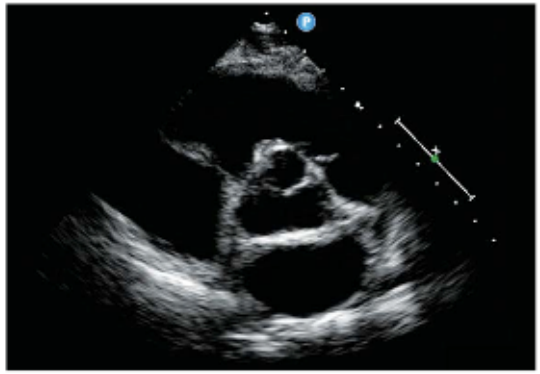

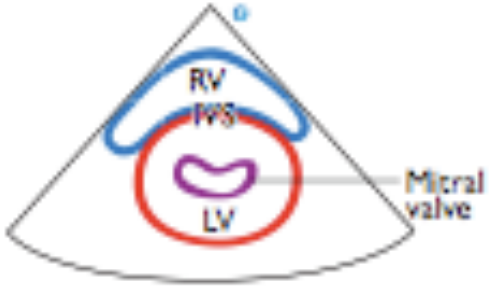
RV
IVS
Mitral valve
LV

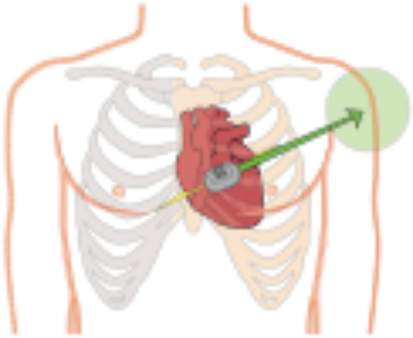

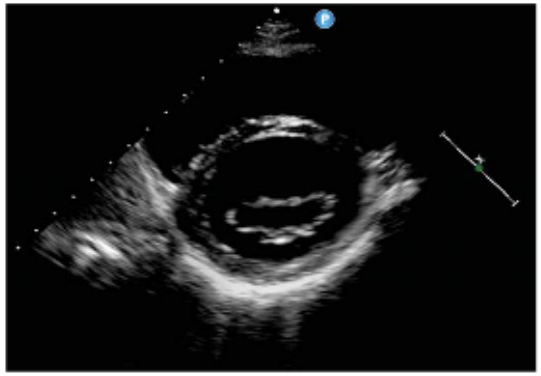

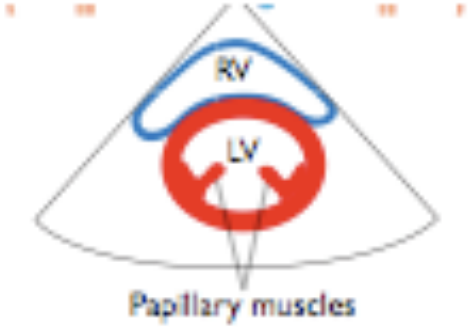
RV
LV
Papillary muscles

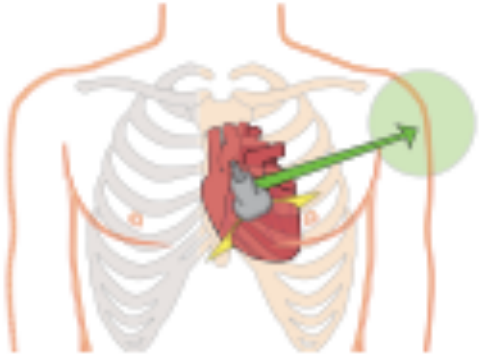

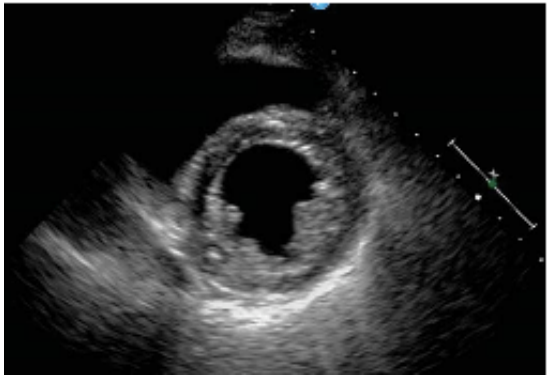

Parasternal Short Axis View

- Assessment of :
  - LV size and function
  - RV size and function
  - Aortic valve
  - Mitral valve
  - Presence of wall motion abnormalities

Apical 4-Chamber View

- Place transducer at the apical impulse, usually just inferior and medial to the left nipple (may need to scan more lateral in some patients)
- Indicator points towards the left flank (approx 3 o'clock)
- Optimal depth: 14-18cm

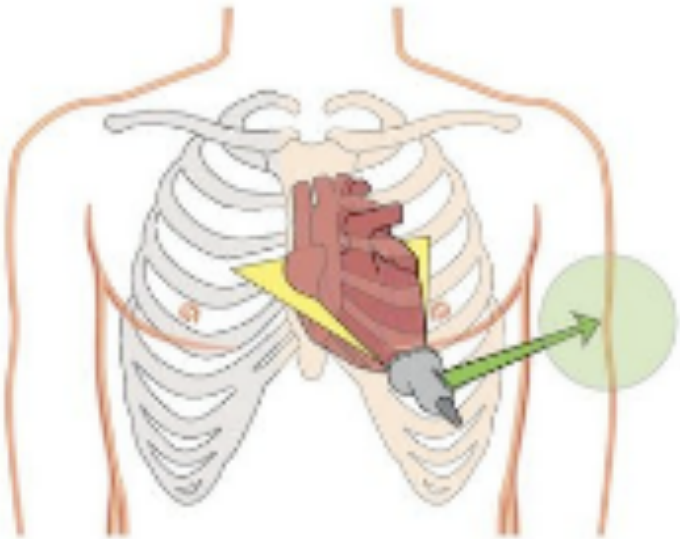

Apical 4-Chamber View

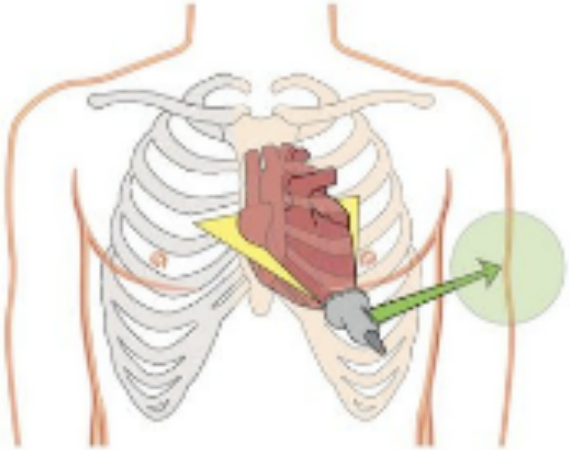

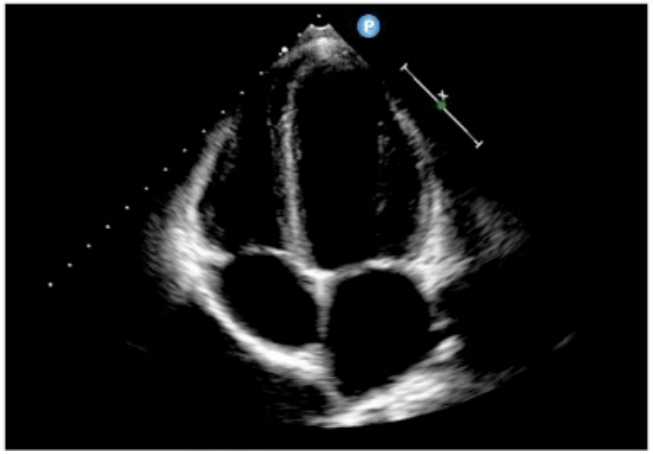

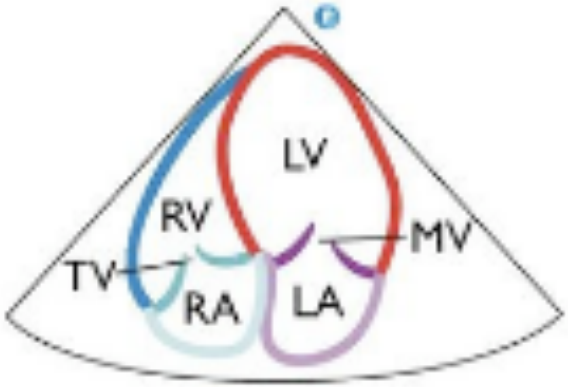

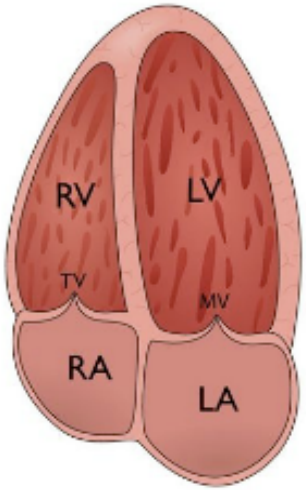

Apical 4-Chamber View

- Assessment of:
  - Left Ventricle and Atrium
  - Right Ventricle and Atrium
  - Aortic Valve
  - Mitral Valve
  - Tricuspid Valve

Subcostal 4-Chamber View

- Place transducer 2-3cm below xyphoid process
- Direct transducer toward the left shoulder
- Indicator probe should be directed towards the left shoulder (approx 3 o'clock)
- Optimal depth: 16-24 cm

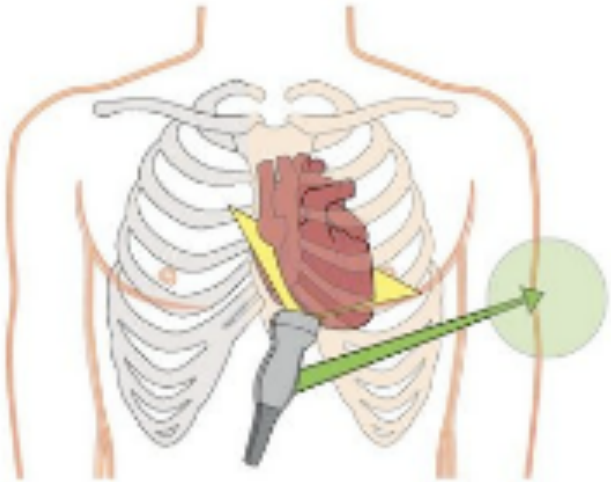

Subcostal 4-Chamber View

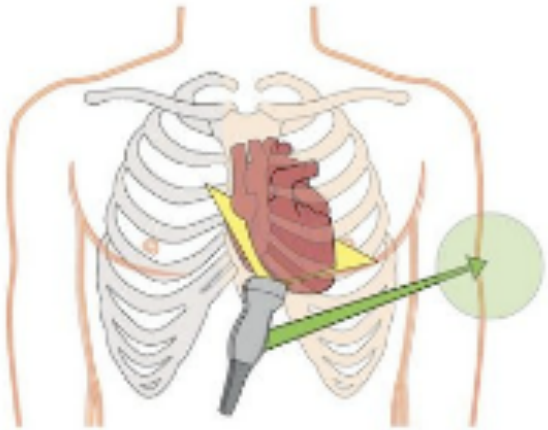

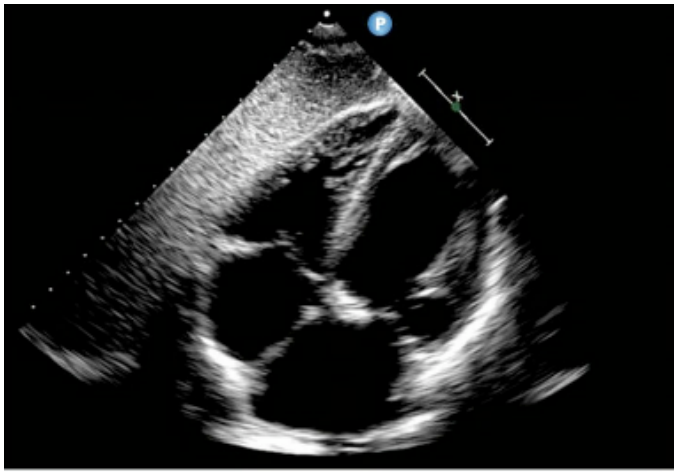

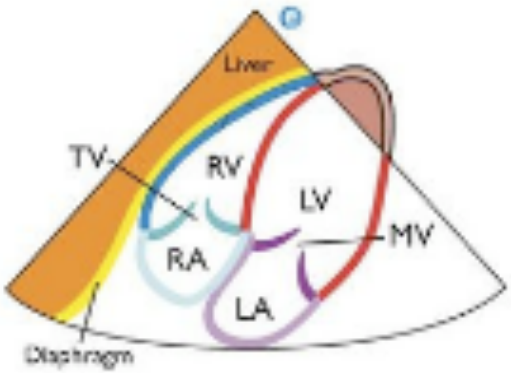

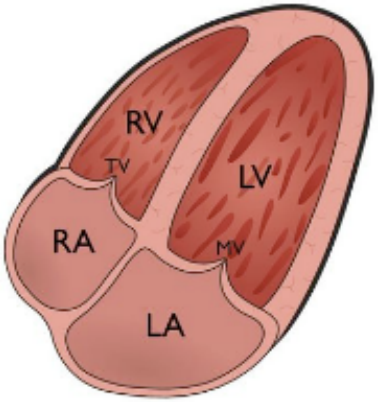

Subcostal 4-Chamber View

- Assessment of:
  - Left Ventricle and Atrium
  - Right Ventricle and Atrium
  - Mitral Valve
  - Tricuspid Valve
  - Pericardium

Subcostal Inferior Vena Cava

- From the subcostal 4-chamber view, rotate the transducer 90°counter-clockwise
- Probe indicator points towards the head (12 o'clock)
- Important to see IVC merging into RA

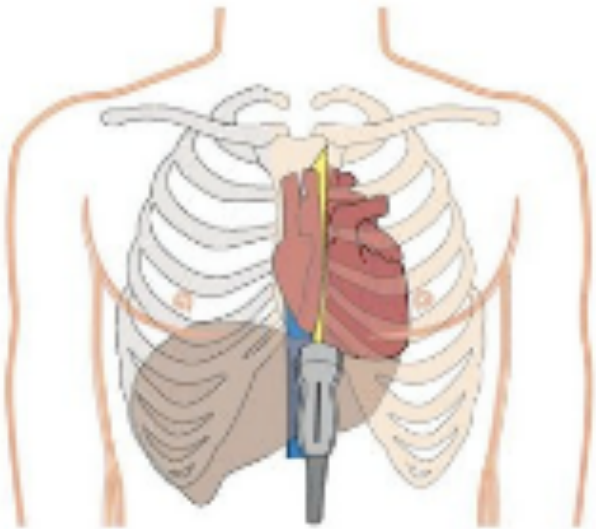

Subcostal Inferior Vena Cava

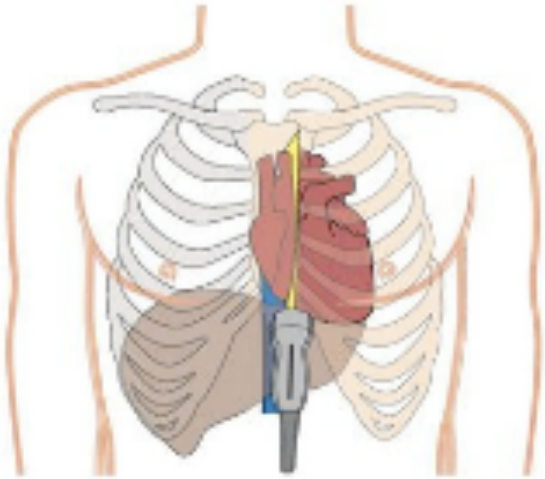

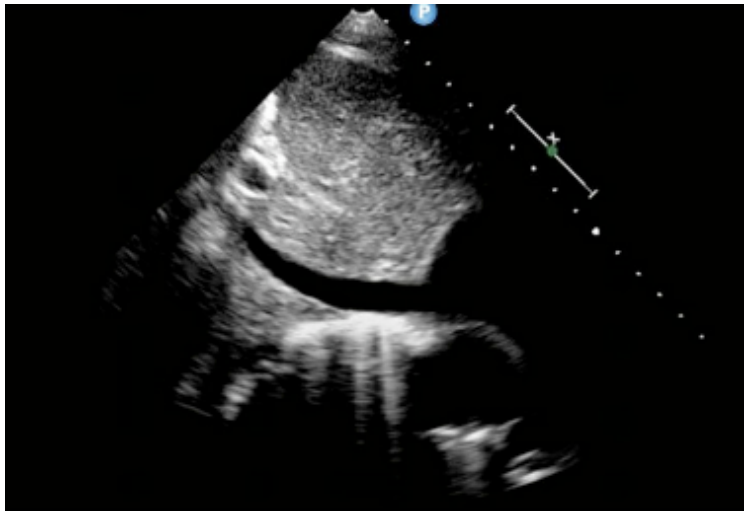

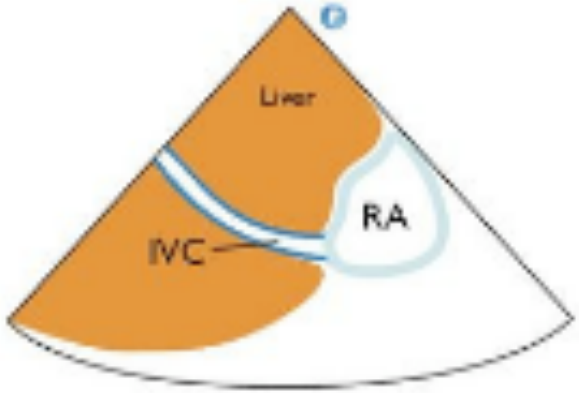

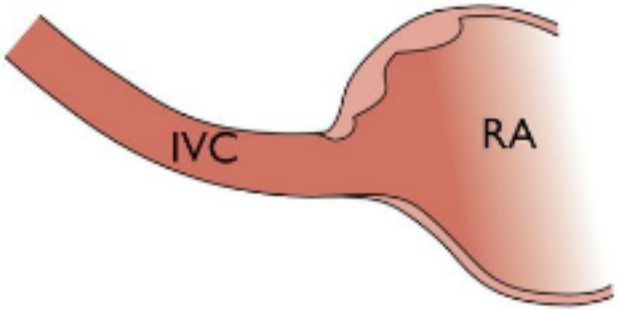

Inferior Vena Cava

- Measure IVC diameter 2-3 cm inferior to the IVC/RA junction

Spontaneous Ventilating Patients

- An IVC collapse of greater than 50% during the respiratory cycle is strongly predictive of a low RA pressure (less than 10mmHG)

Mechanically Ventilated Patients

- IVC respiratory variation is a good predictor of pre-load responsiveness.
- Small IVC (<1.2cm) has a 100% specificity (but low sensitivity) for a RA pressure of less than 10mmHg.

References

1. Beraud, A. Introduction to Transthoracic Echocardiography. Philips Tutorial. http://viewer.zmags.com/publication/9c7aeaf8#/9c7aeaf8/1.
2. KircherBJ, HimelmanRB, SchillerNB.Noninvasive estimation of right atrial pressure from the inspiratory collapse of the inferior vena cava. Am J Cardiol. 1990;66(4):493-496.
3. NagdevAD, MerchantRC, Tirado-GonzalezA, SissonCA, MurphyMC. Emergency department bedside ultrasonographic measurement of the caval index for noninvasive determination of low central venous pressure. Ann Emerg Med. 2010;55(3):290-295.
4. BarbierC, LoubieresY, SchmitC,etal. Respiratory changes in inferior vena cava diameter are helpful in predicting fluid responsiveness in ventilated septic patients. Intensive Care Med. 2004;30(9):1740-1746

5. Other resources:
    1. https://web.stanford.edu/group/ccm_echocardio/cgi-bin/mediawiki/index.php/Main_Page
    2. Tamingthesru.com
    3. https://lagunita.stanford.edu/courses/Medicine/FocusedTTE/OnGoing/about