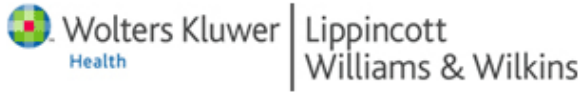

# Full Text



## Cervical Spine Movement during Laryngoscopy with the Bullard, Macintosh, and Miller Laryngoscopes

Author(s): Hastings, Randolph H. MD, PhD; Vigil, A. Christopher MD; Hanna, Richard BS; Yang, Bor-Yau MD; Sartoris, David J. MD

Issue: Volume 82(4), April 1995, pp 859-869

Publication Type: [Clinical Investigation]

Publisher: © 1995 American Society of Anesthesiologists, Inc.

(Hastings) Assistant Professor in Residence, Department of Anesthesiology, and VA Staff Physician.

(Vigil) Resident, Department of Anesthesiology.

(Hanna) Visiting Medical Student.

(Yang) Fellow, Department of Radiology.

Institution(s): (Sartoris) Associate Professor in Residence, Department of Radiology, and VA Staff Physician.

Received from the Anesthesiology Service and Radiology Service, San Diego Department of Veterans Affairs Medical Center, La Jolla, California, and the Departments of Anesthesiology and Radiology, University of California, San Diego, San Diego, California. Submitted for publication August 17, 1994. Accepted for publication December 13, 1994.

Address reprint requests to Dr. Hastings: Department of Anesthesiology, VA Medical Center 125, 3350 La Jolla Village Drive, La Jolla, California 92161-5085.

ISSN:

0003-

3022

Accession:

00000542-

199504000-

00007

Email

Jumpstart

Find

Citing

Articles

<<

Table

of

Contents

About

this

Journal

>>

### Table of Contents:

<< The Maximum Depth of an Atracurium Neuromuscular Block Antagonized by Edrophonium to Effect Adequate Recovery.

>> Thermoregulatory Vasoconstriction Impairs Active Core Cooling.

### Links

- Abstract
- Complete Reference
- External Resolver Basic

### Outline

- Abstract
- Methods
- Results

### Abstract

Background: Direct laryngoscopy requires movement of the head, neck, and cervical spine. Spine movement may be limited for anatomic reasons or because of cervical spine injury. The Bullard laryngoscope, a rigid fiberoptic laryngoscope, may cause less neck flexion and head extension than conventional laryngoscopes. The purpose of this study was to compare head extension (measured externally), cervical spine extension (measured radiographically), and laryngeal view obtained with the Bullard, Macintosh, and Miller laryngoscopes.

Methods: Anesthesia was induced in 35 ASA 1-3 elective surgery patients. Patients

- Dermographics and Anesthetic
- Head Extension
- Cervical Spine Extension
- Laryngeal View
- Soft-tissue Displacement
- Discussion
  - Critique of Method
- REFERENCES

lay on a rigid board with head in neutral position. Laryngoscopy was performed three times, changing between the Bullard, Macintosh, and Miller laryngoscopes. Head extension was measured with an angle finder attached to goggles worn by the patient. The best laryngeal view with each laryngoscope was assessed by the laryngoscopist. In eight patients, lateral cervical spine radiographs were taken before and during laryngoscopy with the Bullard and Macintosh blades.

**Results:** Median values for external head extension were 11 degrees, 10 degrees, and 2 degrees with the Macintosh, Miller, and Bullard laryngoscopy ( $P < 0.01$ ), respectively. Significant reductions in radiographic cervical spine extension were found for the Bullard compared to the Macintosh blade at the atlantooccipital joint, atlantoaxial joint, and C3-C4. Median atlantooccipital extension angles were 6 degrees and 12 degrees for the Bullard and Macintosh laryngoscopes, respectively. The larynx could be exposed in all patients with the Bullard but only in 90% with conventional laryngoscope ( $P < 0.01$ ).

**Conclusions:** The Bullard laryngoscope caused less head extension and cervical spine extension than conventional laryngoscopes and resulted in a better view. It may be useful in care of patients in whom cervical spine movement is limited or undesirable.

## Graphics

- [Figure 1](#)
- [Figure 2](#)
- [Table 1](#)
- [Figure 3](#)
- [Figure 4](#)
- [Figure 5](#)
- [Figure 6](#)
- [Table 2](#)
- [Figure 7](#)

---

Key words: Anesthetic techniques: tracheal intubation. Radiography: cervical

spine. Spine: atlantooccipital joint; cervical vertebrae.

DIRECT laryngoscopy depends on extension of the head at the atlantooccipital joint to align the oral, pharyngeal, and laryngeal axes. In anesthetized elective surgery patients, the head must be extended approximately 15 degrees to expose the vocal cords. [1] The cervical spine between the occiput and C3 is extended about 45 degrees during laryngoscopy. [2]

Direct laryngoscopy may be difficult if spine movement is limited because of arthritis, disk disease, other spine abnormalities, or a small gap between the occiput and the spinous process of the atlas. [3-5] On the other hand, the spine movement with laryngoscopy may be dangerous in patients with cervical spine injury because of the possibility of causing new neurologic deficits. [6,7] There are two case reports of quadriplegia in patients with unrecognized cervical spine injuries, demonstrating that airway management can result in neurologic injury in this setting. [6,7].

Various airway management techniques may be employed in situations where cervical spine movement must be limited.

For example, direct laryngoscopy technique is modified by the addition of maneuvers to stabilize the head and neck in cases with potential cervical spine injury. Hastings and Wood found that head extension was reduced during laryngoscopy if an assistant held the head firmly against the table. [1] Specialized laryngoscopes and other airway equipment have been designed with the objective of minimizing head movement during tracheal intubation. The Bullard laryngoscope (Circon ACMI, Stamford CT) is an anatomically shaped, rigid laryngoscope that uses fiberoptic technology to view the larynx, potentially eliminating the need for neck flexion or head extension. It has been recommended for patients with potential cervical spine injuries as a method of intubating the trachea while maintaining neutral head and neck position. [8,9] The laryngoscope also might be useful

in patients with limited mobility of the cervical spine. However, controlled studies have not been done to measure the amount of head movement or cervical spine movement during laryngoscopy with the Bullard laryngoscope.

The purpose of this study was to compare head and neck movement during laryngoscopy with the Macintosh, Miller, and Bullard laryngoscopes in anesthetized, elective surgery patients. Patients lay on a rigid board without a pillow to reproduce, in part, the conditions enforced for patients with potential cervical spine injuries. In 35 patients, we measured head extension with an angle finder mounted on the side of the head [1] during laryngoscopy with each laryngoscope. In a subset of those patients, we also measured cervical spine movement radiographically.

## Methods

The subjects were ASA physical status 1 or 2 adult patients scheduled for elective surgery requiring anesthesia and endotracheal intubation. Exclusion criteria included history of cervical spine injury or abnormality, full stomach, or gastroesophageal reflux disease. Patients gave written informed consent. The study was approved by the Human Subjects Committee of the University of California, San Diego.

Patients were classified by age, weight, and hyomental distance. One of the investigators (RHH or ACY) assessed oropharyngeal view, using the classification system described by Malampatti et al. [10] and modified by Samssoon and Young. [11] The seated patient opened his or her mouth as wide as possible and protruded the tongue without vocalization. Classifications were defined as follows: 1 = uvula, tonsillar pillars, and soft palate visible; 2 = everything but the tonsillar pillars visible; 3 = only the soft and hard palate visible; and 4 = only hard palate visible. In most cases, the anesthetist who would perform the laryngoscopy made his or her own independent assessment.

The Macintosh and Miller laryngoscopes were compared in each of the first eight patients before a Bullard laryngoscope became available to us. The Bullard, Macintosh, and Miller laryngoscopes were used in each of the remaining 27 patients. The order in which the laryngoscopes were used was assigned randomly at the start of the study, based on numbers drawn from a random number table.

Laryngoscopy was performed by the anesthesia resident or nurse anesthetist scheduled to provide anesthesia care. The anesthesia residents participating in this study had 5-35 months of training and were accomplished at direct laryngoscopy in uncomplicated cases. All laryngoscopists had been instructed in the use of the Bullard laryngoscope and had practiced laryngoscopy and tracheal intubation on a mannequin and in at least two patients. To perform laryngoscopy, the Bullard laryngoscope blade, with an endotracheal tube mounted on the intubating stylet, was inserted in the patient's mouth with the long axis of the laryngoscope handle oriented horizontally over the patient's chest. Once the blade and tube had passed the tongue, the laryngoscope handle was rotated to an upright position, and the blade was dropped into the posterior pharynx. A scooping motion was used to lift the blade up against the posterior surface of the tongue, retracting the epiglottis anteriorly. Gentle upward traction was used to obtain the view of the glottis. An endotracheal tube was mounted on the stylet even when tracheal intubation was planned with the Macintosh or Miller laryngoscope. The adult Bullard laryngoscope is made in only one size, but the length can be increased by a plastic blade extender (Circon ACMI). The blade extender was used routinely, because we found in pilot experiments that it was difficult to trap the epiglottis without it

in many of our patients. Blade size for the other laryngoscopes was chosen by the laryngoscopist based on patient size. Macintosh 3 or 4 blades and Miller 2 or 3 blades were used.

The experiment was conducted as follows: The patient lay supine on the operating table with a rigid board extending from the shoulders to the occiput. Premedication was given at the discretion of the anesthetist delivering anesthesia care. Anesthesia was induced after preoxygenation. Twenty-four patients received 4 mg/kg intravenous sodium thiopental or 1-2 mg/kg propofol. Eleven patients were enrolled in a concurrent, unrelated study of drug pharmacokinetics. These patients received 150 micro gram/kg intravenous midazolam and 1.5 micro gram/kg sufentanil for induction. Intravenous vecuronium, 0.1-0.15 mg/kg, was given to all patients for muscle relaxation. Laryngoscopy was performed, and measurements were made after loss of all four twitches from the train-of-four obtained by ulnar nerve stimulation at the wrist.

Head extension angle was measured with a commercial angle finder mounted on the left temple of a pair of plastic goggles designed for eye protection during racquet sports. The goggles were secured snugly on the patient's head with a strap. The head was placed flat on the board in neutral position, judged by aligning the occlusal surface of the maxillary molars or gums perpendicular to the floor. [12] The angle finder was adjusted to read 0 degree. The anesthetist was instructed to perform laryngoscopy as they normally would, with one restriction, to keep the occiput in contact with the rigid board at all times. The purpose of this constraint was to mimic the posture imposed for cervical spine protection in trauma patients with possible injuries. An observer, kneeling to the patient's left, verified that the head was not lifted and cautioned the laryngoscopist if the occiput began to come off the board. Cricoid pressure and manual head and neck stabilization maneuvers were not used. The laryngoscopist attempted to expose the arytenoid cartilages first and then tried to obtain the best possible view of the vocal cords. The observer recorded the degrees of head extension for arytenoid exposure and best view. If the arytenoid cartilages could not be exposed, the best view was taken as the endpoint. The lungs were ventilated between laryngoscopies if necessary, the head was returned to neutral position, the 0 degree reading was confirmed, and laryngoscopy was repeated with a different laryngoscope. The endotracheal tube was placed only once, after the measurements for the third laryngoscopy. The laryngoscopist graded the views obtained with each laryngoscope using the system of Cormack and Lehane [13]; grade 1 = most of the glottis visible, grade 2 = no more than the arytenoid cartilages visible, grade 3 = epiglottis only visible, and grade 4 = failure to expose even the epiglottis.

In eight patients, movement of the cervical spine was investigated radiographically as well. A mobile x-ray machine (GE AMX 4) was positioned to expose a lateral view of the patient's cervical spine from 6 feet. A baseline radiograph was taken with the patient's head and neck in neutral position before induction of anesthesia. During laryngoscopy, one radiograph was taken at the point of exposing the arytenoid cartilages, and a second was taken when the best view of the larynx was obtained. Five radiographs were taken for each patient: the baseline film and two each during laryngoscopy with the Bullard laryngoscope and the Macintosh laryngoscope. The Miller laryngoscope was not included in this part of the study to minimize radiation exposure of the patients, the laryngoscopist, and the observer recording head extension angles. In all of the radiographs, the cervical spine was well defined from the occiput to C4, and measurements were made in this region.

Two radiologists with subspecialty training in musculoskeletal imaging independently measured vertebral body angles.

One radiologist (BYY) was unaware of the purpose of the study. The other, one of the investigators (DJS), knew that the purpose was to compare laryngoscopes but was not familiar with any of the instruments. He had no knowledge of the head extension angle and laryngeal view results. Radiographs from all patients were masked to patient identity and analyzed in random order. Reference lines were drawn for C2, C3, and C4 through the basal plates of the respective vertebral bodies (Figure 1). The reference line for C1 was the tangent between the anterior and posterior arch. The McGregor line, which connects the most dorsal and caudal portion of the occiput and the dorsal edge of the hard palate, was the reference line for the occiput. Reference lines for adjacent levels were often separated by only a few degrees and sometimes intersected at a point off the radiograph. Therefore, we believed that it was more accurate to measure the angle between each reference line and a common, fixed line on the radiograph (Figure 1) and to calculate the angles between adjacent reference lines by difference. On each radiograph, the common line was the upper horizontal edge of the radiograph. The radiologists measured angles with a goniometer.

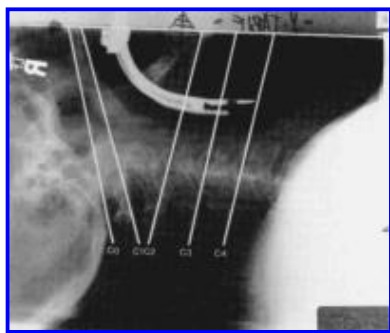


Figure 1. Sample radiograph displaying reference lines for each vertebral level: Occiput (C0), through caudal posterior portion of occiput and hard palate; C1, tangent between the anterior and posterior arch of the atlas; and C2, C3, and C4, through posterior and anterior basal plate of the respective vertebral bodies. Laryngoscopy is performed with the Bullard laryngoscope. The reference lines for adjacent levels, except for C1 and C2, are nearly parallel and do not intersect on the radiograph. Therefore, angles were measured with a goniometer between the reference lines and a common line, the upper horizontal edge of the radiograph. Angles between adjacent levels were calculated by difference. For example, C1-C2 angle - (C1 to common line angle) - (C2 to common line angle). Positive angles denoted extension, and negative angles denoted flexion. The other measurement made on these radiographs was the distance from the anterior margin of the C4 vertebral body, at its midpoint, to the tip of the Bullard or Macintosh laryngoscope blade. The intubating stylet of the Bullard laryngoscope lies approximately 1 cm below the blade extender. The light carrier and fiberoptic bundle lie between the stylet and the blade extender, approximately 2 cm proximal to the end of the stylet.

[\[Help with image viewing\]](#)

[\[Email Jumpstart To Image\]](#)

The amount of soft-tissue displacement achieved by upward lift applied with the Macintosh and Bullard laryngoscopes was estimated by measuring the distance from the midpoint of the anterior margin of C4 to the tip of the laryngoscope on the radiographs (Figure 1). Two individuals independently made this measurement also. The image of the laryngoscope was used as a standard to correct for differences in magnification between radiographs. Magnification factors were calculated from the ratio of the length of the laryngoscope tip on the image (from the tip of the Macintosh laryngoscope to the flange or from the tip of the Bullard laryngoscope to the fiberoptic bundle) to the length of the tip on the actual laryngoscope.

Demographic data, anesthetic doses, and vertebral body-laryngoscope tip distances are presented as mean plus/minus SEM. Data for head extension angles and cervical spine angles are presented as median (lower quartile-upper quartile). The change in cervical spine extension during laryngoscopy was calculated from the difference in angles between the radiograph during laryngoscopy and the baseline radiograph. Angles and laryngoscopy grades were compared between laryngoscopes with the Friedman test, a nonparametric test used when several treatments are performed on the same subject. Significant pairwise differences in angles were determined by Wilcoxon's signed-rank test, using the Bonferroni correction for multiple comparisons. Extension angles were analyzed with nonparametric statistics, because our data suggested that

head extension angles were not distributed normally. In addition, Fitzgerald and colleagues observed that cervical spine extension angles measured during laryngoscopy were not distributed normally. [2] The angle between the occiput and C4 was compared with the head extension angle by linear regression. Vertebral body-laryngoscope distances were compared between Macintosh and Bullard laryngoscopes by paired t test. The distribution of this data did not deviate obviously from normalcy. Laryngoscopy grades were compared between patients with class 1, 2, or 3 oropharyngeal views by the Kruskal-Wallis test for nonparametric analysis of variance. Significance was accepted at the  $P < 0.05$  level.


## Results

### Dermographics and Anesthetic

The 35 patients, all male veterans, averaged 50 plus/minus 3 yr of age (range 22-72 years), distributed relatively evenly by decade. Patients weighed 84 plus/minus 3 kg (range 62-135 kg). Thirteen of the patients had class 1 oropharyngeal views, 16 patients were class 2, and 6 patients were class 3. Hyomental distance averaged 5.5 plus/minus 0.2 cm and ranged from 3 cm (one patient) to 8 cm (two patients). In 24 patients, the anesthetic administered before laryngoscopy consisted of 1 plus/minus 0.2 mg midazolam, 320 plus/minus 50 micro gram fentanyl, and either 365 plus/minus 30 mg sodium thiopental or 170 plus/minus 20 mg propofol. The 11 patients in the concurrent drug study received 9 plus/minus 1 mg midazolam and 95 plus/minus 8 micro gram sufentanil. All of the patients received vecuronium, an average dose of 9.5 plus/minus 0.2 mg.

### Head Extension

Externally measured head extension during laryngoscopy was significantly less with the Bullard laryngoscope than with the other two instruments for both arytenoid exposure and best view ( $P < 0.01$ , Figure 2). Angles were always less with the Bullard than with the Macintosh or Miller laryngoscopes ( $P < 0.05$ ), with differences on the order of 10 degrees. Head extension was not affected by order of laryngoscopy or anesthetic regimen. Head extension angles for the Macintosh and Miller blades were not significantly different (difference 2 degrees (-2 degrees, 4 degrees)). However, head extension varied between the two laryngoscopes in individual patients. Six patients stood out from the others. Head extension with the Macintosh laryngoscope was greater than with the Miller by 9-14 degrees in this group, whereas the difference in the other 29 patients ranged from -5 to 5 degrees. The six patients were not obviously different from the other patients in terms of age, weight, Malampatti classification, hyomental distance, or anesthetic. The laryngeal view was grade 2 with the Macintosh and grade 1 with the Miller laryngoscope in all six patients.



**Figure 2.** Comparison of head extension during laryngoscopy with the three laryngoscopes. These plots show the population statistics, median and quartile values, for head extension angles measured externally with the angle finder in 35 patients for the Macintosh and Miller laryngoscopes and in 27 patients for the Bullard laryngoscope. Outlying points are shown above the columns. Data on the left are for arytenoid exposure, on the right for best view of the larynx. Median values are denoted by white lines across the columns. The 25th and 75th percentile values are represented by the boundaries between the stippled and hatched portions of the columns. The 10th and 90th percentile values are located at the lower and upper ends of the columns, respectively. The Macintosh arytenoid values are labeled as an example, to the left of the column. More than 25% of the patients had 0 degree head extension with the Bullard blade, thus separate 10th percentile values are not shown. The asymmetry of the upper and lower quartile values around the median suggests that head extension angles are not distributed

[\[Help with image viewing\]](#)

[\[Email Jumpstart To Image\]](#)

normally, \* P < 0.05, Bullard versus other two laryngoscopes.

## Cervical Spine Extension

The eight patients who were studied radiographically averaged 56 plus/minus 4 yr of age (range 37-72 yr), weighed 85 plus/minus 6 kg (range 62-107 kg), and had an average hyomental distance of 5.4 plus/minus 0.2 cm (range 4-6 cm). Two patients had class 1 oropharyngeal views, five patients were class 2, and one was class 3.

(Table 1) lists the average angles between adjacent levels from the occiput (C0) to C4 before laryngoscopy with the head and neck in neutral position. Figure 3 shows representative radiographs for the two laryngoscopes. Laryngoscopy with the Macintosh laryngoscope caused extension at C0-C1 and C1-C2 in all patients. There was greater than 10 degrees extension at C3-C4 in three patients. With the Bullard laryngoscope, the most movement occurred at C1-C2. Extension at C0-C1 and C3-C4 and overall extension between C0 and C4 were significantly less with the Bullard laryngoscope than with the Macintosh laryngoscope for both arytenoid exposure (data not shown) and best view (Figure 4, P < 0.05). However, the change in spinal alignment with the Bullard blade was greater than the amount of head extension. For example, some patients had an 8-10 degrees increase in atlantooccipital or atlantoaxial extension, while head extension was 5 degrees or less. Because movement occurred at C3-C4 as well as in the upper cervical spine, we examined the relationship between head extension angle and the angle between the occiput and C4. Figure 5 shows the angle between the occiput and C4 plotted versus head extension angle. The two variables correlated significantly ( $r^2 = 0.7$ ) with a slope of 1.2 plus/minus 0.5. Interobserver variability in vertebral body angle measurement averaged 2 degrees (N = 40 radiographs).

	Baseline	Bullard	Macintosh	P-Value
Age (yr)	56.0 ± 4.2	55.8 ± 4.1	56.2 ± 4.3	0.5
Weight (kg)	85.0 ± 5.1	84.5 ± 5.0	85.5 ± 5.2	0.8
Hyomental distance (cm)	5.4 ± 0.2	5.3 ± 0.2	5.5 ± 0.2	0.3
Class 1 oropharyngeal views	2/8	1/8	1/8	0.5
Class 2 oropharyngeal views	5/8	5/8	5/8	0.5
Class 3 oropharyngeal views	1/8	1/8	1/8	0.5

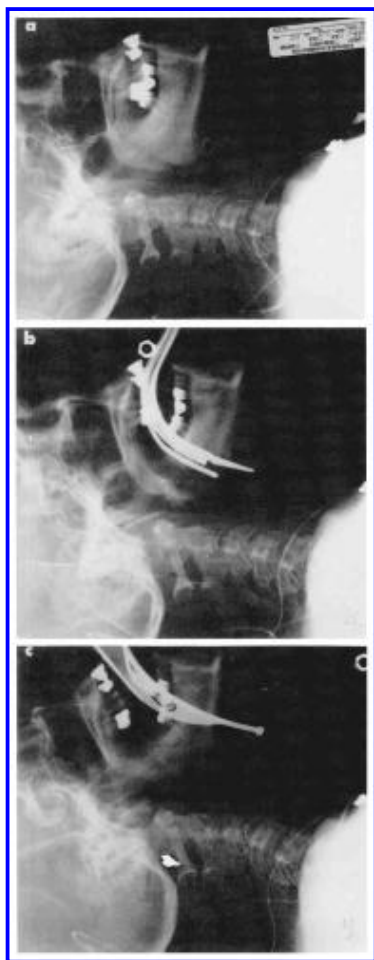
Table 1. Baseline Angles between Adjacent Cervical Levels with Head in Neutral Position

[\[Help with image viewing\]](#)

[\[Email Jumpstart To Image\]](#)

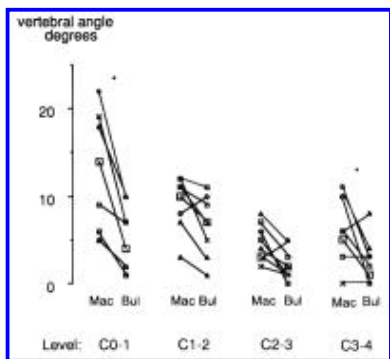
Figure 3. Lateral radiographs taken in one patient showing the condition of the cervical spine at baseline (a) and during laryngoscopy with best laryngeal view with the Bullard (b) and Macintosh (c) laryngoscopes. Cervical spine angles in each film are representative of the median values from the study. Cervical spine extension is greater with the Macintosh laryngoscope. For example, the spine is much more curved in c than in a or b. In addition, the gap between the occiput and the spinous process of C1 is much smaller in c than in a or b, indicating greater extension at the atlantooccipital joint. The distance from the vertebral column to the laryngoscope blade tip is less in b than in c, showing that the Bullard blade is not lifted as much anteriorly as the Macintosh blade. The radio-opaque circle overlying the patient's skull in c is a part on the angle finder, attached to the patient's head.





[\[Help with image viewing\]](#)

[\[Email Jumpstart To Image\]](#)

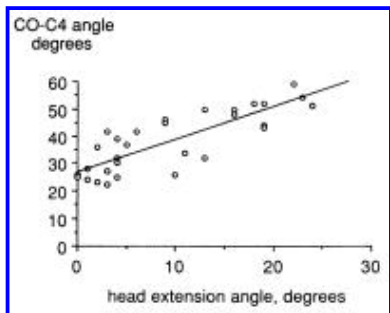


[\[Help with image viewing\]](#)

[\[Email Jumpstart To Image\]](#)

Figure 4. Cervical spine extension during laryngoscopy with best laryngeal view. The ordinate shows the difference in angles between the radiography with laryngoscopy and the baseline radiograph for each joint in the cervical spine from the atlas-to-occipital joint (C0-C1) to C3-C4. The points represent individual patients, and line segments connect the data from the same patient for the Macintosh and Bullard laryngoscopes. Angle measurements by the two radiologists were averaged. Similar results were obtained for cervical spine extension with arytenoid exposure (not shown). \*P < 0.05.





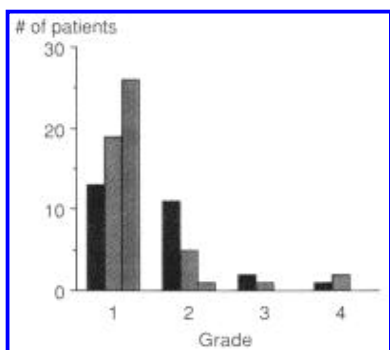
**Figure 5.** Comparison of the head extension angle with the angle between the occiput and C4 (C0-C4 angle). The C0-C4 angle is the angle measured between the C0 and C4 reference lines on the radiograph. Data are included for arytenoid exposure and best view for both the Macintosh and Bullard laryngoscopes. Head extension angle correlated significantly with C0-C4 angle ( $r^2$  0.7). Regression line: head extension angle  $27 + 1.19 \times \text{C0-C4 angle}$ . Head extension angle also was correlated with the angles at C0-C1 and C1-C2 (data not shown).

[\[Help with image viewing\]](#)

[\[Email Jumpstart To Image\]](#)

## Laryngeal View

The quality of the laryngeal view depended on laryngoscope (**Figure 6**,  $P < 0.01$ ). The Bullard laryngoscope grade was better than the Macintosh grade in 12 of 28 patients and better than the Miller grade in 7 patients. The fiberoptic laryngoscope never presented an inferior view and provided a grade 1 view of the glottis in all of the patients except one (**Figure 6**). The view was grade 2 in one patient because the epiglottis could not be retracted with the blade. The choice between Macintosh and Miller laryngoscopes did not have a consistent effect on view. The laryngeal view was better with the Macintosh blade in 7 patients and the Miller blade in 8 patients and was the same in 17 patients. Laryngoscopists reported that a grade 1 view with the conventional laryngoscopes consisted of 25-75% of the vocal cords. None of them attempted to obtain a view beyond what they normally expected for tracheal intubation.



**Figure 6.** Effect of laryngoscope on laryngeal view. Laryngeal view was assessed by the scheme of Cormack and Lehane: grade 1 = full view, grade 2 = arytenoid cartilages visible only, grade 3 = only epiglottis visible, and grade 4 = epiglottis not visible. The ordinate shows the number of patients with each grade. The dark bars, hatched bars, and stippled bars represent the Macintosh, Miller, and Bullard laryngoscopes, respectively. The 27 patients shown here underwent laryngoscopy with all three laryngoscopes. The eight patients studied with only the Macintosh and Miller laryngoscopes are not included. The laryngeal view with the Bullard laryngoscope was always equal or superior to the view with the other two laryngoscopes.  $P < 0.01$ .

[\[Help with image viewing\]](#)

[\[Email Jumpstart To Image\]](#)

The degree of difficulty of glottic visualization with Macintosh and Miller laryngoscopes was related to oropharyngeal view classification also. The more difficult laryngoscopies, with higher grades, were more likely to occur in patients with class 2 or 3 oropharyngeal views (**Table 2**,  $P < 0.05$ ).

Laryngoscope	Oropharyngeal View				Laryngoscopic View			
	0	1	2	3	1	2	3	4
Bullard	0	0	0	0	0	0	0	0
Macintosh	0	0	0	0	0	0	0	0
Miller	0	0	0	0	0	0	0	0

Table 2. Relationship between Oropharyngeal View and Laryngoscopic Grade

[\[Help with image viewing\]](#)

[\[Email Jumpstart To Image\]](#)

## Soft-tissue Displacement

The distance from the C4 vertebral body to the laryngoscope tip with arytenoid exposure and with best view was greater with the Macintosh laryngoscope than with the Bullard blade in every patient. The average distances were 3.6 plus/minus 0.2 cm versus 1.7 plus/minus 0.2 cm (arytenoid exposure) and 4.1 plus/minus 0.2 cm versus 2.2 plus/minus 0.2 cm (best view) for the Macintosh and Bullard laryngoscopes, respectively ( $P < 0.05$ ). Interobserver variability averaged 0.2 plus/minus 0.1 cm. The variation in magnification factors between radiographs was trivial, with a coefficient of variation of 5%.

## Discussion

This study directly compared the function of three different laryngoscopes in anesthetized elective surgical patients lying flat with occiputs in contact with a rigid board. Manual stabilization, cricoid pressure, and immobilizing devices, which are also components of standard techniques for direct laryngoscopy of trauma patients with potential cervical spine injuries, were not employed. Successful laryngoscopy occurred with less head extension and less extension of the cervical spine when the Bullard laryngoscope was used compared to the Macintosh and Miller laryngoscopes. Complete glottic exposure resulted in 1 degree (0 degree, 4 degree lower and upper quartiles) head extension with the Bullard laryngoscope and approximately 11 degrees (9 degrees, 19 degrees) with the Macintosh and Miller blades, similar to results in our previous study. [1] Spine movement was less with the Bullard laryngoscope than with the Macintosh, but some spine extension occurred with the Bullard. Extension with the Bullard was approximately 17 degrees (12 degrees, 22 degrees) between the occiput and C4, measured radiographically, compared to 31 degrees (28 degrees, 46 degrees) with the Macintosh. For comparison, the maximum rotation between the occiput and C6 in normal adults is approximately 60 degrees, [14,15] roughly twice the change in angle we measured during laryngoscopy with the Macintosh laryngoscope and 3.5 times the movement with the Bullard laryngoscope. The Macintosh laryngoscope appeared to require greater soft-tissue displacement than the Bullard laryngoscope to achieve comparable laryngeal exposure. This is based on the observation that the distance from the vertebral column to the laryngoscope blade was uniformly greater with the conventional laryngoscope.

In addition to causing more head, neck, and spine movement, the conventional laryngoscopes were less successful in exposing the larynx than was the Bullard blade. The incidence of grade 3 or 4 views with the Macintosh and Miller laryngoscopes in our study was 11 plus/minus 5%. This is significantly greater than the incidence in general surgery patients (with no restrictions on intubating technique), between 0.3% and 3% in different reports ( $P < 0.01$ ). [12,16,17] Nolan and Wilson also found a high incidence of grade 3 views in patients treated with heads flat on the table and manual stabilization. [18] Our patients were positioned with head flat on a rigid board, but manual stabilization was not used. Thus, the lack of the sniffing position may increase the difficulty of laryngoscopy. The Bullard laryngoscope surmounted postural impediments in our study. Because of its fiberoptic technology, the Bullard laryngoscope does not depend on positioning to align oral, pharyngeal, and laryngeal axes. Cooper et al. found that tracheal intubation with the Bullard laryngoscope was equally easy in patients who displayed

grades 1 and 3 laryngoscopic views with the Macintosh laryngoscope, [19] as in the current study.

It is important to retract the epiglottis with the Bullard blade. The laryngeal view is worse, and more upward lift is required if the blade tip is placed in the vallecula as with a Macintosh blade (Figure 7).

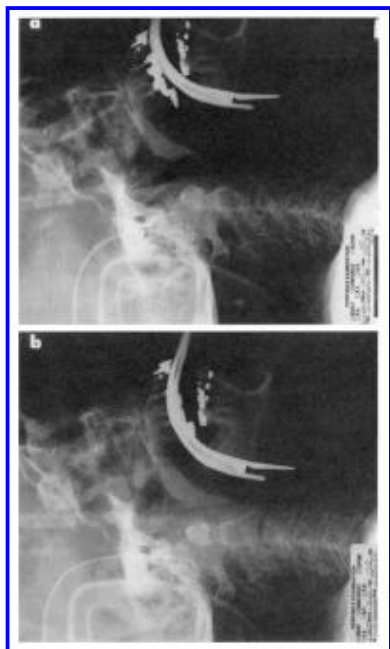


Figure 7. Radiographs demonstrating the importance of retracting the epiglottis with the Bullard laryngoscope. In a, the tip of the laryngoscope is in the vallecula, lifting the hyoepiglottic ligament. Only the arytenoid cartilages are visible to the laryngoscopist, even though the blade is lifted 4.4 cm away from the vertebral column, farther than in radiograph b. The blade is retracting the epiglottis in b, and a full view of the larynx is obtained with lift of only 2.2 cm.

[\[Help with image viewing\]](#)

[\[Email Jumpstart To Image\]](#)

This work presents convincing evidence that head movement and cervical spine displacement are less with the Bullard than with the Macintosh or Miller laryngoscopes under the conditions of the study. Our conclusions clearly apply to the clinical management of male surgical patients without spine disease anesthetized electively. The study included patients over a wide range of age and weight who would be expected to present varying degrees of difficulty for tracheal intubation based on oropharyngeal view classification and hyomental distance. [20] However, the relevance of the study for patients with cervical spine pathology or injuries may be limited because of differences in conditions. In contrast to the study patients, anesthesia care of trauma patients is complicated by a greater sense of urgency, the presence of injuries of varying degrees, and the use of manual head stabilization and cricoid pressure during laryngoscopy, maneuvers that may alter the amount of head extension or the view. It is also uncertain whether the results would apply to patients with cervical spine disease or limited mobility, compared to the patients with normal spines studied here.

Many techniques, in addition to the Bullard laryngoscope, have been proposed for minimally invasive tracheal intubation of patients with cervical spine disease or injuries. These include flexible fiberoptic laryngoscopy, retrograde wire techniques, blind nasotracheal intubation, the Augustine guide, the light wand, retraction blade laryngoscopes, and direct laryngoscopy with the gum elastic bougie. Each technique requires additional training and has its own set of advantages and disadvantages. Many of these methods do not absolutely depend on head extension and may cause less head and neck disturbance than

would direct laryngoscopy. To our knowledge, the only controlled studies of spine movement during tracheal intubation have compared direct laryngoscopy with the Bullard laryngoscope (in the current study) or the Augustine guide. The Augustine guide is an instrument designed to elevate the epiglottis and guide the endotracheal tube into the trachea blindly. Fitzgerald and colleagues found that tracheal intubation with the Augustine guide could be accomplished with less extension than with direct laryngoscopy. [2] The median angle between the occiput and C3 was 46 degrees for direct laryngoscopy and 26 degrees for the Augustine guide. Our measurements for this portion of the cervical spine were similar: 45 degrees with the Macintosh and 34 degrees with the Bullard laryngoscope. The Bullard laryngoscope and the Augustine guide reduce spine movement with intubation to similar extents, but it is unknown whether this would improve outcome variables, such as incidence of secondary neurologic injury or failed intubation.

We compared the Macintosh and Miller laryngoscopes because we believed that head and spine movement might be different with the two instruments. Laryngoscopy technique is different with a curved blade than with a straight blade. The tip of a curved laryngoscope tip is placed in the vallecula, exerting upward and forward force on the hyoepiglottic ligament to elevate the epiglottis indirectly. In contrast, the straight blade is used to lift the epiglottis directly. Thus, a straight blade might obtain a better view of the larynx and require less head and neck movement than a curved blade. Majernick et al. found no difference in cervical spine movement during laryngoscopy with the Macintosh and Miller laryngoscopes in four anesthetized volunteers. [21] Overall, our results are similar and show no significant difference in head extension or spine movement between the Macintosh and Miller instruments. However, the blade made a difference in individual patients. In particular, the degree of head extension with the Macintosh blade exceeded that with the Miller blade by a clinically significant amount in six patients. We were unable to identify what was different about these patients compared to the others in whom the two blades were close to equivalent. The size and shape of the epiglottis might be a factor. One would expect that a straight blade would be superior to a curved blade if the patient had a long, floppy epiglottis.

#### Critique of Method

The current study and a previous one [1] used an external measurement of head movement to estimate movement of the cervical spine during laryngoscopy. Noninvasive methods often are used in orthopedics to quantify spine movement. These methods correlate well with radiographic methods. Mayer et al. observed a strong correlation between estimates of range of motion in the lumbar spine [22] or the cervical spine [23] made with inclinometers and the actual range of motion measured radiographically. In this study, we validated our angle finder measurements radiographically. Head extension angle correlated with extension of the cervical spine at several levels (data not shown) and overall between the occiput and C4, as shown in Figure 5. As head extension increased, extension in the spine increased also, with a slope close to 1.

It was impossible to blind the laryngoscopist or observer to the order in which the three laryngoscopes were used. This could have introduced bias in the amount of extension performed by the laryngoscopist or in the observer's angle measurement. However, the degrees of head extension for arytenoid exposure and best view with the Macintosh and Miller laryngoscopes were similar to results in our previous study using the Macintosh laryngoscope. [1] Each of the anesthetists seemed motivated to perform as well as possible, and the effort exerted seemed dependent on the difficulty of the individual laryngoscopy. Furthermore, the head extension measurements are supported by the radiographic measurements in

demonstrating less movement with the Bullard laryngoscope. Radiographic biases were possible also, because the laryngoscopes appeared on the radiographs. We believe that bias of this nature was unlikely for a number of reasons. First, the two radiologists were unfamiliar with the instruments. One radiologist did not know the purpose of the study, and the other states that he ignored the image of the laryngoscope when analyzing the radiographs. In addition, the radiographs were shuffled, and patient identity was masked to prevent biases in the matched comparisons of data for each patient. Finally, the angle measurements with a goniometer were precise. The lines were drawn through well defined bony landmarks and could vary no more than the width of the pencil mark. The potential variation in angle measurement was less than 2 degrees, as demonstrated by the low interobserver variability.

Assessments of oropharyngeal view and laryngeal grade are qualitative and open to interpretation. Therefore, only two individuals, using the same criteria, assessed oropharyngeal view for the study. Our method, with the patient seated, head in sniffing position, and tongue protruding, provides the best prediction of difficult laryngoscopy and the best reproducibility. [20] Neither the angle observer or the laryngoscopist were blinded to this information, but this could not affect our comparison of the three laryngoscopes, because all three laryngoscopes were studied in each patient. The endpoints for measuring head extension angle depended on the laryngoscopists' assessment of laryngeal view. The two points, arytenoid exposure and best view, were chosen to represent lower and upper limits for the movement that would be necessary to visualize the glottis in a given patient. By their own report, none of the laryngoscopists attempted to achieve exposure beyond their normal view, approximately 25-27% of the vocal cords. Therefore, we believe the data accurately reflect head extension and spine extension that might occur in clinical practice. Interobserver variability in assessing grade would have no impact on our results, because the data for different laryngoscopes are matched for a given patient and laryngoscopist. Intraobserver variability in performing laryngoscopy to a specific endpoint is low. Head extension angles for arytenoid exposure or best view are reproducible on repeat measurements within plus/minus 1 degree. [1].

This study compared the function of three laryngoscopes in anesthetized, elective surgical patients with heads flat on a board and necks straight. Head extension, cervical spine extension, and soft-tissue displacement in the neck were less with the Bullard laryngoscope than with the Macintosh or Miller laryngoscopes. The Bullard laryngoscope caused some spine extension with laryngeal exposure, about 6 degrees at the atlantooccipital joint and 7 degrees at the atlantoaxial joint, compared to 12 degrees and 11 degrees, respectively, with the Macintosh laryngoscope. The larynx could be exposed in all patients with the Bullard but only in 90% of the patients with conventional laryngoscopes ( $P < 0.01$ ). Head and spine movement and laryngeal view did not differ significantly between the Macintosh and Miller laryngoscopes. The Bullard laryngoscope may be useful in patients in whom head and neck movement is limited or undesirable.

The authors thank Greg Loshak, of Circon ACMI, for the loan of the Bullard laryngoscope used in this study.

## REFERENCES

1. Hastings RH, Wood PR: Head extension and laryngeal view during laryngoscopy with cervical spine stabilization maneuvers. *ANESTHESIOLOGY* 80:825-831, 1994. [Ovid Full Text ExternalResolverBasic Bibliographic Links \[Context Link\]](#)
2. Fitzgerald RD, Krafft P, Skrbensky G, Pernerstorfer T, Steiner E, Kapral S, Weinstabl C: Excursions of the cervical spine during tacheal intubation: Blind oral intubation compared with direct laryngoscopy. *Anaesthesia* 49:111-115, 1994. [\[Context Link\]](#)

3. Brechner VL: Unusual problems in the management of airways: Flexion-extension mobility of the cervical vertebrae. *Anesth Analg* 47:362-373, 1968. [\[Context Link\]](#)
4. White A, Kander PL: Anatomical factors in difficult direct laryngoscopy. *Br J Anaesth* 47:468-474, 1975. [ExternalResolverBasic Bibliographic Links \[Context Link\]](#)
5. Nichol HC, Zuck D: Difficult laryngoscopy: The "anterior" larynx and the atlanto-occipital gap. *Br J Anaesth* 55:141-144, 1983. [ExternalResolverBasic Bibliographic Links \[Context Link\]](#)
6. Salathe M, Johr M: Unsuspected cervical fractures: A common problem in ankylosing spondylitis. *ANESTHESIOLOGY* 70:869-870, 1989. [Ovid Full Text ExternalResolverBasic Bibliographic Links \[Context Link\]](#)
7. Hastings RH, Kelley SD: Neurologic deterioration associated with airway management in a cervical spine-injured patient. *ANESTHESIOLOGY* 78:580-583, 1993. [Ovid Full Text ExternalResolverBasic Bibliographic Links \[Context Link\]](#)
8. Saunders PR, Giesecke AH: Clinical assessment of the adult Bullard laryngoscope. *Can J Anaesth* 36:S118-S119, 1989. [\[Context Link\]](#)
9. Borland LM, Casselbrant M: The Bullard laryngoscope: A new indirect oral laryngoscope (pediatric version). *Anesth Analg* 70:105-108, 1990. [Ovid Full Text ExternalResolverBasic Bibliographic Links \[Context Link\]](#)
10. Mallampati SR, Gugino LD, Desai SP, Waraksa B, Freiburger D, Lui P: A clinical sign to predict difficult tracheal intubation: A prospective study. *Can Anaesth Soc J* 32:429-434, 1985. [\[Context Link\]](#)
11. Samsoun GLT, Young JRB: Difficult tracheal intubation: A retrospective study. *Anaesthesia* 42:487-490, 1987. [ExternalResolverBasic Bibliographic Links \[Context Link\]](#)
12. Bellhouse CP, Dore' C: Criteria for estimating the likelihood of difficulty of endotracheal intubation with the Macintosh laryngoscope. *Anaesth Intensive Care* 16:329-337, 1988. [ExternalResolverBasic Bibliographic Links \[Context Link\]](#)
13. Cormack RS, Lehane J: Difficult tracheal intubation in obstetrics. *Anaesthesia* 42:1105-1111, 1984. [\[Context Link\]](#)
14. Johnson RM, Hart DL, Simmons EF, Ramsby GR, Southwick SO: Cervical orthoses: A study comparing their effectiveness in restricting cervical motion in normal subjects. *J Bone Joint Surg* 59A:332-339, 1977. [\[Context Link\]](#)
15. Dvorak J, Panjabi MM, Novotny JE, Antinnes JA: In vivo flexion/extension of the normal cervical spine. *J Orthopaedic Res* 9:828-834, 1991. [\[Context Link\]](#)
16. Williams KN, Carli F, Cormack RS: Unexpected difficult laryngoscopy: A prospective survey in routine general surgery. *Br J Anaesth* 66:38-44, 1991. [ExternalResolverBasic Bibliographic Links \[Context Link\]](#)
17. Oates JDL, Macleod AD, Oates PD, Pearsall FJ, Howie JC, Murray GD: Comparison of two methods for predicting difficult intubation. *Br J Anaesth* 66:305-309, 1991. [ExternalResolverBasic Bibliographic Links \[Context Link\]](#)
18. Nolan JP, Wilson ME: Orotracheal intubation in patients with potential cervical spine injuries. *Anaesthesia* 48:630-633, 1993. [ExternalResolverBasic Bibliographic Links \[Context Link\]](#)
19. Cooper SD, Benumof JL: Evaluation of the Bullard laryngoscope using the new intubating stylet: Comparison with conventional laryngoscopy. *Anesth Analg* 79:965-970, 1994. [Ovid Full Text ExternalResolverBasic Bibliographic Links \[Context Link\]](#)

20. Lewis M, Keramati S, Benumof JL, Berry CC: What is the best way to determine oropharyngeal classification and mandibular space length to predict difficult laryngoscopy. ANESTHESIOLOGY 81:69-75, 1994. [Ovid Full Text](#)  
[ExternalResolverBasic Bibliographic Links](#) [[Context Link](#)]

21. Majernick TG, Bienick R, Houston JB, Hughes HG: Cervical spine movement during orotracheal intubation. Ann Emerg Med 15:417-420, 1986. [ExternalResolverBasic Bibliographic Links](#) [[Context Link](#)]

22. Mayer TG, Tencer AF, Kristoferson S, Mooney V: Use of noninvasive techniques for quantification of spinal range-of-motion in normal subjects and chronic low-back dysfunction patients. Spine 9:588-595, 1984. [Ovid Full Text](#)  
[ExternalResolverBasic Bibliographic Links](#) [[Context Link](#)]

23. Mayer T, Brady S, Bovasso E, Pope P, Gatchel RJ: Noninvasive measurement of cervical tri-planar motion in normal subjects. Spine 10:2191-2195, 1993. [[Context Link](#)]

---

Copyright (c) 2000-2007 [Ovid Technologies, Inc.](#)

Version: OvidSP\_UI01.01.02, SourceID 35095