

Intraoperative Localization of an Epileptogenic Focus with Alfentanil and Fentanyl

Pirjo H. Manninen, MD, FRCPC*, Sharon J. Burke, MBBS, FRCA*, Richard Wennberg, MD, FRCPC†, Andres M. Lozano, MD, PhD, FRCSC‡, and Hossam El Beheiry, MBBCH, FRCPC*

Departments of *Anaesthesia, †Neurology, and ‡Neurosurgery, University of Toronto, The Toronto Hospital, Western Division, Toronto, Ontario, Canada

We evaluated the effectiveness of alfentanil and fentanyl in stimulating epileptogenic activity during surgery for intractable temporal lobe epilepsy under general anesthesia. Ten patients received a standardized anesthetic induction with IV fentanyl 5 $\mu\text{g}/\text{kg}$, propofol 3–5 mg/kg, and atracurium 0.5 mg/kg. Maintenance was with isoflurane, 70% $\text{N}_2\text{O}/30\% \text{O}_2$, and an atracurium infusion. After dural opening, droperidol 0.02 mg/kg was administered IV. Both inhaled anesthetics were discontinued and verified to be at 0 end-tidal concentration before the study. Baseline electrocorticography over the surface of the temporal lobe and depth electrode recordings in the amygdala and hippocampus were obtained, followed by 10 min of recording before and after the IV administration of both alfentanil 50 $\mu\text{g}/\text{kg}$ and fentanyl 10 $\mu\text{g}/\text{kg}$. Any changes in cardiovascular variables were documented. The number of interictal epileptiform spikes at the most active site for each patient was tabulated before and after the

administration of each drug. Both alfentanil and fentanyl induced an increase in spike activity in all patients. Alfentanil was more potent, increasing the median number of spikes per epoch from 18 to 58, compared with fentanyl (20 to 42 spikes) ($P < 0.05$). Alfentanil had a shorter duration of action (4.9 ± 1.3 min) compared with fentanyl (8.5 ± 2 min) ($P < 0.009$). In nine patients, the most active site was the hippocampus or amygdala. There was a decrease in mean blood pressure, but only after the administration of alfentanil ($P < 0.05$). Two patients had electrographic evidence of seizure activity. These opioids can be used to assist in the localization of the epileptogenic focus during surgery. **Implications:** Both alfentanil and fentanyl activate epileptiform activity in patients with temporal lobe epilepsy. These opioids can be used to assist in the localization of the epileptogenic focus during surgery.

(Anesth Analg 1999;88:1101–6)

Patients with intractable partial seizures may be amenable to surgical treatment to eliminate or decrease the frequency of their seizures. This surgery most commonly involves the excision of a temporal lobe epileptogenic focus. Before surgery, patients are investigated to determine the approximate location of the focus. Further localization is performed intraoperatively with electrocorticography (ECoG) using electrodes placed directly on the cortex after the brain has been exposed (1–3). Epilepsy surgery can be performed with the patient awake or under general anesthesia. The ability to monitor ECoG is more difficult during general anesthesia, as the anesthetics influence the recordings by suppressing electrical brain activity. It is often necessary to chemically stimulate the epileptogenic activity to aid in the localization of

the epileptogenic focus. Many different drugs have been used to activate epileptiform activity, including methohexital, thiopentol, propofol, enflurane, and ketamine (4–6). Both alfentanil and fentanyl have also been shown to increase epileptiform activity in patients with epilepsy (7–9). The purpose of this study was to compare the effectiveness of alfentanil and fentanyl in activating the epileptogenic focus during surgical resection for intractable temporal lobe epilepsy in adults under general anesthesia.

Methods

After approval from the institutional ethics review board and written, informed consent, we studied 10 patients with epilepsy undergoing surgical resection of an epileptogenic focus under general anesthesia. All patients had medically intractable temporal lobe epilepsy. One patient had previously undergone resection of an anterior temporal lobe tumor, which showed no evidence of recurrence. Preoperatively, the

Accepted for publication February 11, 1999.

Address correspondence and reprint requests to Pirjo H. Manninen, MD, Department of Anaesthesia, The Toronto Hospital, Western Division, 399 Bathurst St., Toronto, Ontario, Canada M5T 2S8.

epileptogenic region was localized using prolonged scalp electroencephalography (EEG) and video monitoring, combined with the results of neuropsychological testing and magnetic resonance imaging (MRI). The patients continued receiving their regular anticonvulsant medication until the time of surgery. No preoperative medication was given. The anesthetic management of the patients was standardized. Routine monitors included electrocardiogram, pulse oximetry, blood pressure by intraarterial catheter, esophageal temperature, and continuous end-tidal CO₂, nitrous oxide, and isoflurane concentrations. Anesthesia was induced with IV fentanyl 5 µg/kg, propofol 3–5 mg/kg, and atracurium 0.5 mg/kg or succinylcholine 1.5 mg/kg. The trachea was intubated, and the lungs were ventilated to maintain arterial CO₂ partial pressure within 35–38 mm Hg. Anesthesia was maintained with 70% nitrous oxide, 30% oxygen, isoflurane, and additional fentanyl, as required, during insertion of the head pins and during the craniotomy. Bupivacaine 0.5% with epinephrine was used at the sites of pin insertion and for the scalp incision. The patient's temperature was maintained within normal limits. Muscle relaxation was maintained with an infusion of atracurium, titrated to two twitches on a train-of-four test.

After the craniotomy and opening of the dura, and approximately 20 minutes before ECoG monitoring, isoflurane was discontinued. ECoG electrodes (either carbon balls or steel discs) were placed over the exposed lateral temporal cortex and immediately above the Sylvian fissure over frontocentral cortex. In addition, two four-contact depth electrodes were inserted orthogonally through the second temporal gyrus with their tips situated to record from the region of the amygdala and anterior hippocampus, respectively. Droperidol 0.02 mg/kg IV was administered. Nitrous oxide was also discontinued to prevent any depression of electrical activity of the brain. Before diagnostic ECoG monitoring, isoflurane and nitrous oxide end-tidal concentrations were both verified to be 0. During the preoperative assessment, the patient had been warned of the possibility of awareness during the time of ECoG recording.

All ECoG monitoring was performed by the neurologist-electroencephalographer (RW). After 10 min of steady-state recording for a baseline, patients received the first study drug, IV alfentanil 50 µg/kg. ECoG was continued for at least 10 min or until the return of baseline activity, including disappearance of alfentanil-induced slow-wave activity. IV fentanyl 10 µg/kg was administered, and the ECoG was observed for another 10 min. During the ECoG recordings, the blood pressure and heart rate were continuously monitored and documented before and

0, 3, 5, and 10 min after each study drug administration. Any change in cardiovascular variables was noted.

Although not part of this study, the management of two of the patients included the use of motor cortex mapping after the ECoG recordings. This involved discontinuing muscle relaxation and the administration of additional doses of fentanyl. When all testing was completed, the anesthetic was resumed with the addition of nitrous oxide, isoflurane, and muscle relaxation.

The ECoG was interpreted by the neurologist (RW) and neurosurgeon (AL) during the procedure, and the findings were incorporated into the final surgical planning. ECoG results were quantified with respect to the activation effects of alfentanil and fentanyl by the neurologist postoperatively when the entire study was completed. Epileptiform activity (spikes and sharp waves) was identified using the same criteria outlined for scalp EEG by Gloor (2). The number of epileptic spikes or sharp waves (hereafter referred to collectively as spikes) per epoch was tabulated from the most active site for each patient. An epoch was arbitrarily defined as a duration of 1 min, and the epileptiform activity was quantitated for 5 min before and after each drug administration. Any evidence of electrographic seizure activity was documented. ECoG data before, during, and after drug administration for the 10 patients were analyzed as the median, minimal, and maximal number of spikes per epoch. Comparisons among baseline, drug effects, and recovery were performed using Freedman two-way analysis of variance with multiple comparisons using Wilcoxon test. Baseline was defined as the number of spikes per epoch just before the administration of each study drug, and the drug effect was the number of spikes at the epoch that showed the maximal effect. Recovery was assumed to be the number of spikes at the epoch that showed no change or <10% change from the preceding five epochs. $P < 0.05$ was considered significant.

Results

All 10 patients completed the study. The mean \pm SD age of the patients was 36 ± 9 yr, gender ratio (F:M) was 4:6, and weight was 76 ± 15 kg. The total dose of fentanyl used at induction was 4.6 ± 0.9 µg/kg, and the total dose of fentanyl administered before the ECoG study was 5.9 ± 1.3 µg/kg. The time interval from the last dose of fentanyl to the study was 142 ± 61 min. The median number of spikes per epoch and the cardiovascular changes before and after the administration of each study drug are shown in Table 1. Both alfentanil and fentanyl induced an increase in spike activity in all patients, but alfentanil was more

Table 1. Results

	Alfentanil		Fentanyl	
	A Before	B After	C Before	D After
Spike activity ^d	18	58*	20	42†
MAP (mm Hg)	100 ± 15	80 ± 15 (3 min)‡ 75 ± 12 (5 min)‡ 79 ± 12 (10 min)‡	86 ± 14	84 ± 14 82 ± 15 83 ± 16
Heart rate (bpm)	75 ± 15	66 ± 14 (3 min) 62 ± 10 (5 min) 61 ± 10 (10 min)	60 ± 8	60 ± 8 61 ± 9 61 ± 10

Values are mean ± sd.

MAP = mean blood pressure.

* $P < 0.05$ versus A, C, and D.

† $P < 0.05$ versus A and C.

‡ $P < 0.05$ versus A.

^d Median number of spikes per epoch.

potent (Figure 1A). The most active site was the hippocampus or amygdala in nine patients. In the one patient with previous temporal lobe tumor resection, the most active site was on the previous resection margin of the inferior temporal gyrus. Nine of the 10 patients showed spontaneous spikes before chemical activation at what was subsequently defined as the most active site. In these patients, the site of maximal activation (hippocampus and/or amygdala or, in the patient with previous tumor resection, inferior temporal gyrus) was identical to the localization of the most abundant spontaneous spiking. In the other patient, who had MRI-evidenced and pathologically confirmed mesial temporal sclerosis, alfentanil and fentanyl activation induced spiking restricted to the hippocampus and amygdala.

In apparent contrast to the activating effects of other chemicals used during ECoG (e.g., methohexital), which tend to increase limbic and temporal neocortical spiking to a similar degree in patients with independent mesial and lateral interictal epileptiform activity (6), no significant activation of the relatively infrequent independent spikes recorded over temporal neocortex in six of the nine patients with limbic-maximal spiking was seen after the administration of alfentanil or fentanyl. The other three patients showed no epileptiform activity over temporal neocortex before or after opiate activation. No epileptiform activity was recorded above the Sylvian fissure in any of the patients during this study before or after opiate administration.

The duration of the ECoG-activating effects of alfentanil was 4.9 ± 1.3 min and for fentanyl was 8.5 ± 2 min ($P < 0.009$; two-tailed Student's *t*-test for independent samples). The time interval between the administration of alfentanil and fentanyl was 12 ± 1.6 min. The ECoG had returned to baseline before the administration of fentanyl. Two patients had electrographic seizure activity, one after the administration of alfentanil and the other after the administration of

both alfentanil and fentanyl (Figure 1B). The seizures ceased spontaneously. One patient had a marked increase in blood pressure and heart rate that lasted < 2 min during the seizure after the administration of alfentanil. The overall cardiovascular changes after the administration of the opioids showed a decrease in mean blood pressure, which was significant only after the administration of alfentanil (Table 1). There was no difference among baseline blood pressures, and there were no significant changes in the heart rate. The recovery of the patients was not delayed due to the study drugs, and there were no anesthetic-related complications postoperatively.

All patients underwent standard anterior temporal resection plus amygdalo-hippocampectomy. In the early postoperative period, two patients had a seizure during recovery in the intensive care unit, and three other patients had seizures on the second or third postoperative day. The mean discharge time from the hospital was 5 ± 2 days. Patients were all discharged home with their usual antiepileptic medications. Nine of the 10 patients were seizure-free [Class I of Engel (10) classification] after surgery at 6–18 mo follow-up. The remaining patient showed worthwhile improvement ($>90\%$ reduction in seizure frequency, Class III). Temporal lobe pathology showed hippocampal sclerosis in seven patients, cavernous angioma in one patient, hamartoma in one patient, and gliosis in the patient with previous tumor resection.

Discussion

Alfentanil and fentanyl are routinely used in anesthesia in a wide range of doses. There are numerous reports questioning the relationship of opioids and seizure-like activity in patients (11,12). Most previous studies and case reports have included patients who were not known to have epilepsy. Opioids have not been shown to produce epileptiform activity on EEG monitoring in patients with no history of epilepsy, but they may produce myoclonic movements that may clinically resemble seizure-like activity.

Animal studies have shown that the administration of fentanyl and alfentanil may produce electrographic seizure activity (13,14). In rats, the peri-hippocampal area contains a high density of opioid receptors. Smith et al. (11) attempted to determine whether opioid-induced rigidity represented epileptic seizure activity in patients not known to have epilepsy. They studied 127 patients anesthetized with large doses of fentanyl, sufentanil, and alfentanil. EEG recordings were performed with six surface electrodes, although, in four patients, intranasal electrodes were added to look for "subcortical" activity. Patients' movements and rigidity were clinically assessed, as well as hemodynamic monitoring. Clinically, 46 patients manifested intense

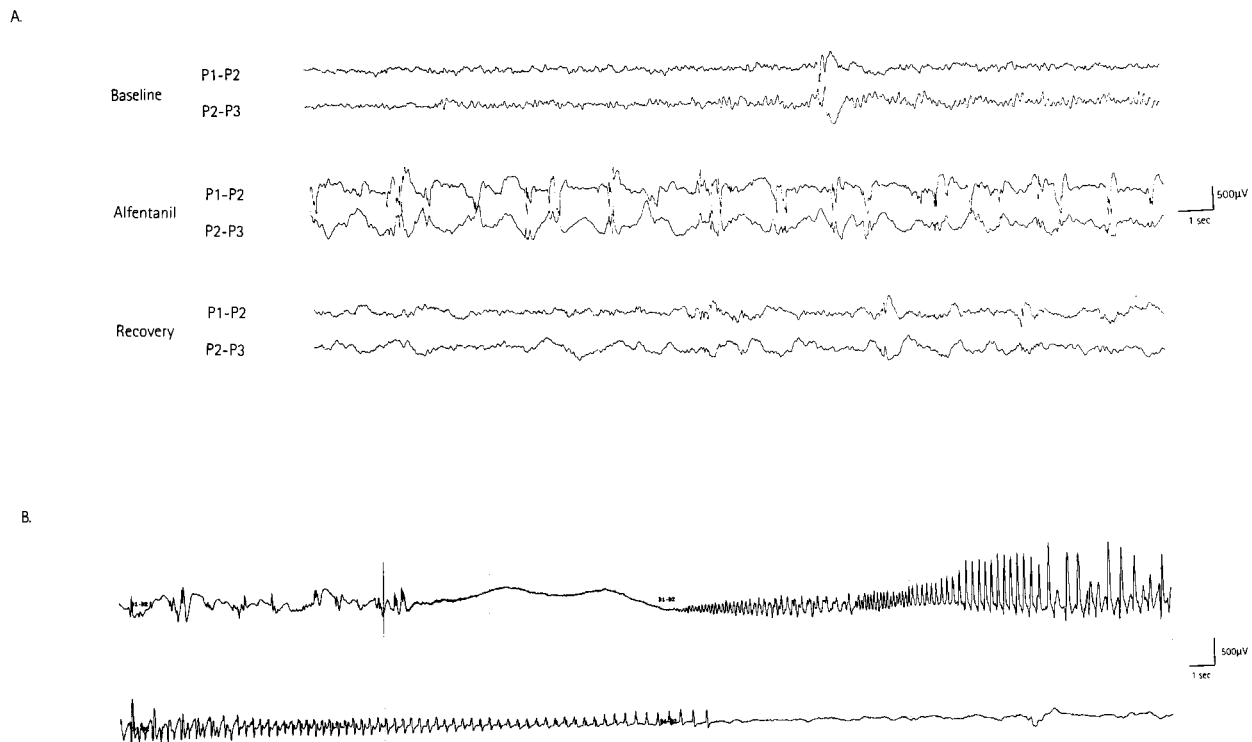


Figure 1. A, Patient 2. Bipolar recordings from right hippocampus before the administration of alfentanil (top), 1 min after the administration of alfentanil (middle), and 5 min after the administration of alfentanil (bottom). Middle tracing shows activation of interictal epileptiform spiking induced by alfentanil. P1, P2, P3 = hippocampal depth electrode contacts; P1 deepest. B, Patient 4. Single channel of bipolar recording from right amygdala showing onset of electrographic seizure 2 min after the administration of alfentanil. Top tracing shows activated interictal spikes followed by seizure onset (abrupt flattening); bottom tracing is continuation of the top and shows seizure offset and postictal attenuation. D1, D2 = amygdala depth electrode contacts; D1 deepest.

rigidity resembling seizures, but the only observed EEG change consisted of small sharp waves related to muscle activity or artifact. There was no epileptiform activity in the limited EEG tracings, nor was there an increase in sympathetic activity indicating epileptic seizures. The authors concluded that most cases of seizure-like activity previously reported were due to opioid-induced rigidity, rather than to epileptic seizures.

Opioids can induce electrographic seizures during ECoG recordings in patients with epilepsy. One study examined the effect of fentanyl in nine patients undergoing surgery for intractable complex partial seizures. Tempelhoff et al. (7) studied patients by using epidural ECoG electrodes implanted 24–72 h before surgery. During surgery, they used a moderate dose of fentanyl during the induction of anesthesia (mean 25.7 µg/kg) while continuously recording the ECoG from both infratemporal regions. Eight patients exhibited electrographic seizures detected in the perihippocampal leads. One interesting finding of this study is that fentanyl also induced electrographic seizures from the contralateral “nonepileptic” temporal lobe in four patients. However, this observation of contralateral seizure induction cannot be interpreted as evidence that fentanyl can induce seizure activity in normal brain

tissue, as the patients were presumably all bitemporal epileptics being investigated with chronic intracranial ECoG to determine the side most responsible for their clinical seizures. The doses used in the study of Tempelhoff et al. (7) were moderate and may not be optimal for use during ECoG performed in the middle of a procedure. Furthermore, they did not analyze interictal spikes, which are the markers of epileptogenesis typically sought during intraoperative ECoG.

Cascino et al. (8) retrospectively studied the effects of IV alfentanil 50 µg/kg in 23 patients during surgery for intractable epilepsy under general anesthesia. ECoG was performed with electrodes placed on the basal and superior surfaces of the temporal lobe and suprasylvian region. Three depth electrodes were inserted into the amygdala and hippocampus. These authors found an increased frequency of interictal epileptiform discharges in 20 patients. One patient had a recorded electrographic seizure. The surgically excised temporal lobes in these patients revealed cortical gliosis and varying degrees of hippocampal neuronal loss in all patients. Alfentanil had no significant effect on spike activity in the suprasylvian region. The maximal effect of alfentanil occurred 30 s to 3 min after the administration of the drug.

Another more recent article reported the effect of alfentanil activation of epileptiform activity in children. Keene et al. (9) studied the effect of 20 $\mu\text{g}/\text{kg}$ alfentanil IV and methohexital 0.5 $\mu\text{g}/\text{kg}$ in 12 patients. Activation of epileptiform activity was considered significant if there was an increase of $\geq 50\%$ after the administration of the drug. Ten patients (83%) had alfentanil-activated epileptiform abnormalities. Three patients (25%) had evidence of electrographic seizures. The activation occurred within 5 min of administration. After the administration of methohexital, only six patients (50%) had activation of epileptiform abnormalities. Many of the patients in the study had a mesial temporal location of their epileptic foci. An increase in heart rate and blood pressure occurred in the three patients who had simultaneously recorded electrographic seizures on ECoG, strongly suggestive of clinical seizures. Muscle relaxants were used; therefore, other physical features were blocked.

One other study of opioid-induced epileptiform activity deserves mention. Kearse et al. (15) studied the effects of the IV administration of fentanyl 100 $\mu\text{g}/\text{kg}$ (given in four divided doses) in patients with no history of epilepsy. Using a full array of scalp EEG electrodes, they described the induction of generalized interictal spikes in almost every patient studied, which were seen to occur (in their illustrations) over a moderately severe generalized background activity disturbance, presumably reflecting the opiate anesthesia. Their interpretation that such generalized spikes could arise from a focal "deep generator source" is questionable, as the potentials recorded by scalp EEG represent electrical activity generated in the superficial cerebral cortex (2). They also noted that spike frequency decreased with increasing serum opioid concentration, likely representing progressive inhibition/suppression of brain electrical activity at the higher concentrations. The observed changes may have represented a dose-related transition to burst-suppression anesthesia, with generalized intermingled spikes and sharp waves at the lighter levels of anesthesia. In any event, the intriguing findings of Kearse et al. (15), who used maximal dosages of fentanyl 10 times those used in this study, are not directly relevant to the observations of focal activation of intracranially recorded epileptiform activity during intraoperative ECoG described herein.

In our study, both alfentanil and fentanyl produced an increase in interictal epileptiform activity on ECoG. The increase was greater, but of shorter duration, with alfentanil. We used a large dose of alfentanil, 50 $\mu\text{g}/\text{kg}$, based on a previous study (8). The dose of fentanyl was chosen to reflect a potency ratio of alfentanil to fentanyl 5:1. We were unable to randomize the order of administration of alfentanil and fentanyl because of the longer duration of action of fentanyl. This large dose given at this time did not interfere with the

emergence from anesthesia of any patient. In practical terms, using fentanyl to activate an epileptic focus is probably not ideal because of its longer duration of action. All patients did receive fentanyl for induction and during the craniotomy, although the time interval from the last dose of fentanyl was 142 ± 61 min. We cannot rule out the effect of some remaining fentanyl on the results of this study, but we also wanted our study to reflect clinical practice. The lingering effects of some alfentanil may have also influenced the results of fentanyl during the study, although our ECoG had returned to baseline.

Two patients had electrographic evidence of seizure activity. Although we were unable to detect any movement because the patients had muscle paralysis, one patient did have an increase in blood pressure and heart rate associated with the electrographic seizure. Otherwise, there was a trend for the blood pressure to decrease after the administration of alfentanil; however, no treatment was required.

The mechanisms underlying opioid-induced epileptogenic activity are poorly understood and require further investigation. Experimental evidence suggests that induction of epileptiform activity may be mediated through opiate activation at multiple receptor subtypes, including ϵ , δ , μ , σ , and κ receptors (16,17). A separate mechanism of activation may be mediated by opiate antagonism of inhibitory GABAergic neurotransmission (18-20). Zhang et al. (21) showed that methohexital potentiates GABA-mediated synaptic inhibition and likely activates epileptiform activity at ECoG through a resulting increase in neuronal synchrony. The similar activation of interictal epileptiform activity seen at ECoG with opiates and barbiturates, apparently acting through opposing effects on central nervous system inhibitory GABAergic transmission, is interesting in that multiple mechanisms may underlie human epileptogenesis. Furthermore, methohexital, unlike the activating opiates, is not prone to induction of ictal electrographic seizure activity at ECoG (6,9) and seems to show less specificity to limbic structures in its activating effects than the opiates.

In conclusion, in this study, we showed that both alfentanil and fentanyl activate epileptiform activity in patients with temporal lobe epilepsy. These opioids can be used to assist in the localization of the epileptogenic focus, as the activating effects seem restricted to regions of epileptogenic brain tissue. Because electrographic seizures were induced in two patients, the dose of alfentanil may not need to be as large as that used in our study. Fentanyl has a longer duration of action, which may limit its usefulness, particularly if different areas of the brain are studied in the same recording session. The question of whether opioids, particularly alfentanil or fentanyl, should be used in

patients with epilepsy in this dose range remains unanswered. Precautions should be taken, however, as these patients did show activation of epileptiform activity, and the possibility of electrographic seizure induction by the opioid is real. Further studies are required to determine the safe dose of opioids in patients with epilepsy. In this study, we showed that these opioids are options to previously known anesthetics for the activation of epileptiform activity at ECoG in patients undergoing epilepsy surgery.

References

1. Jasper H. Electrocorticography. In: Penfield W, Jasper H, eds. *Epilepsy and the functional anatomy of the human brain*. Boston: Little, Brown, 1954:692-738.
2. Gloor P. Contributions of electroencephalography and electrocorticography to the neurosurgical treatment of epilepsies. In: Purpura D, Penry J, Walter R, eds. *Neurosurgical management of the epilepsies*. New York: Raven, 1975:59-105.
3. Ojemann G. Different approaches to resective epilepsy surgery: "standard" and "tailored." *Epilepsy Res* 1992;5:169-74.
4. Eldredge EA, Soriano SG, Rockoff MA. Surgical treatment of epilepsy in children: neuroanesthesia. *Neurosurg Clin North Am* 1995;6:505-20.
5. Kofke WA, Tempelhoff R, Dasheiff RM. Anesthetic implications of epilepsy, status epilepticus, and epilepsy surgery. *J Neurosurg Anesthesiol* 1997;9:349-72.
6. Wennberg R, Quesney F, Olivier A, Dubeau F. Induction of burst-suppression and activation of epileptiform activity after methohexital and selective amygdalo-hippocampectomy. *Electroencephalogr Clin Neurophysiol* 1997;102:443-51.
7. Templehoff R, Modica PA, Bernardo KL, Edwards I. Fentanyl-induced electrocorticographic seizures in patients with complex partial epilepsy. *J Neurosurg* 1992;77:201-8.
8. Cascino GD, So EL, Sharbrough FW, et al. Alfentanil-induced epileptiform activity in patients with partial epilepsy. *J Clin Neurophysiol* 1993;10:520-5.
9. Keene DL, Roberts D, Splinter WM, et al. Alfentanil mediated activation of epileptiform activity in the electrocorticogram during resection of epileptogenic foci. *Can J Neurol Sci* 1997;24:37-9.
10. Engel J. Outcome with respect to epileptic seizures. In: Engel J, ed. *Surgical treatment of the epilepsies*. New York: Raven, 1987: 553-71.
11. Smith NT, Benthuysen JL, Bickford RG, et al. Seizures during opioid anesthesia induction: are they opioid-induced rigidity? *Anesthesiology* 1989;71:852-62.
12. Manninen PH. Opioids and seizures. *Can J Anaesth* 1997;44: 463-6.
13. Tommasino C, Maekawa T, Shapiro HM. Fentanyl-induced seizures activate subcortical brain metabolism. *Anesthesiology* 1984;60:283-90.
14. Kofke WA, Garman RH, Tom WC, et al. Alfentanil-induced hypermetabolism, seizure, and histopathology in rat brain. *Anesth Analg* 1992;75:953-64.
15. Kearse LA, Koski G, Husain MV, et al. Epileptiform activity during opioid anesthesia. *Electroencephalogr Clin Neurophysiol* 1993;87:374-9.
16. Snead OC III. Opiate-induced seizures: a study of mu and delta specific mechanisms. *Exp Neurol* 1986;93:348-58.
17. Snead OC III, Bearden LJ. The epileptogenic spectrum of opiate agonists. *Neuropharmacology* 1982;21:1137-44.
18. Zieglgänsberger W, French ED, Siggins GR, Bloom FE. Opioid peptides may excite hippocampal pyramidal neurons by inhibiting adjacent inhibitory interneurons. *Science* 1979;205:415-7.
19. Werz MA, Macdonald RL. Opiate alkaloids antagonize postsynaptic glycine and GABA responses: correlation with convulsant action. *Brain Res* 1982;236:107-19.
20. Frenk H. Pro- and anticonvulsant actions of morphine and the endogenous opioids: involvement and interactions of multiple opiate and non opiate systems. *Brain Res Rev* 1983;6:197-210.
21. Zhang L, Zhang Y, Wennberg R. Multiple actions of methohexital on hippocampal CA1 and cortical neurons of rat brain slices. *J Pharmacol Exp Ther* 1998;286:1177-82.